

# Evaluation of the Anterior Cruciate Ligament Injury of Knee Joint Using Magnetic Resonances Imaging

Ibtisam Abdallah Fadulemulla<sup>1</sup>, Ashwag Diab AlShammari<sup>2</sup>, Nagwan ElHussein<sup>1</sup>, Sara A Seifeldin<sup>3</sup>, Qurain Turki AlShammari<sup>1\*</sup>

<sup>1</sup>Department of Diagnostic Radiology, College of Applied Medical Sciences, University of Ha'il, Hail, Saudi Arabia. <sup>2</sup>Department of Diagnostic Radiology, King Salman Specialist Hospital, Hail Health Cluster, Ministry of Health, Hail, Saudi Arabia. <sup>3</sup>Department of Clinical Laboratory Science, College of Applied Medical Sciences, University of Ha'il, Hail, Saudi Arabia.

## Abstract

Anterior cruciate ligament (ACL) injury is a common indication for Magnetic Resonance imaging examination, the advancements in Magnetic Resonance imaging have provided the considerable potential for a one-stop shop radiation-free assessment with an all-in-one modality examination of the knee joint. The aim of this study is to the evaluation of the anterior cruciate ligament injury of the knee joint using magnetic resonance imaging. A study was performed to evaluate meniscal and anterior cruciate ligament injury of the knee using MRI. A total of 92 patients were examined in this study. The data was collected from two hospitals (King Salman Specialist Hospital and King Khaled) in the Hail region in Saudi Arabia from January 2022 to July 2022. The study found that (80.4%) of patients are male patients. The highest findings were found in the age groups ranging from 21-40 years old. The most common patient compiling was found knee injuries (31.5%) and the most common findings were ACL sprain (35.9%) and ACL tore. (29.3% ) MR has shown to be very useful in ACL insufficient or deficient and can detect many ACL and Meniscal abnormalities. Our data demonstrated that ACL sprain and ACL tearing the common abnormalities. The study concluded that MRI has a high sensitivity for the detection of ACL, meniscal, and articular cartilage in patients with knee injuries, and so plays a major role in determining the disease's diagnosis and management.

**Keywords:** Anterior cruciate ligament (ACL), Magnetic resonance imaging (MRI), Knee injury, Sport injury

## INTRODUCTION

Sports injuries occur to players or people during sports. However, they may also occur during exposure to an injury unrelated to exercise and may lead to a joint injury similar to sports injuries. In addition, a sports injury may occur either due to an acute injury, such as cutting the cruciate ligament or anterior cruciate ligament, or it may occur due to repetitive stress on a specific area of the body, such as the elbow of a tennis player [1].

Knee injuries are prevalent and also occur in non-players. More than 70% of knee injuries occur due to an indirect injury to the knee that may result in injury to one or more parts of the joint. A meniscal cartilage tear is one of the most common knee injuries. The meniscus is a fibrous cartilage tissue positioned between the two surfaces of the joint that distributes stress and pressure on the articular surface by increasing the area between both sides of the joint [2].

It is an integral part of the joint because its removal leads to increased stress on the articular surface and may lead to early friction in the joint. It is important to note that the meniscus contains blood perfusion in the outer part (approximately the outer third). In contrast, the inner part lacks blood perfusion and cannot heal in the event of an injury [3].

Usually, the injury occurs during exercise and results in a rotational movement in the joint, which may lead to the rupture of the meniscus; in most cases of cartilage ruptures, the pain is not severe, and sometimes the player can continue playing, but the pain increases after hours and is accompanied by gradual joint swelling, then the symptoms continue. The pain usually increases when almost complete flexion of the joint may be accompanied by mechanical symptoms such as joint locking, meaning that the patient cannot fully extend the knee for moments and then extend it after a particular movement, and sometimes accompanied by a crack in the joint. In addition, frequent swelling or oozing may occur in

**Address for correspondence:** Qurain Turki Alshammari, Department of Diagnostic Radiology, College of Applied Medical Sciences, University of Ha'il, Hail, Saudi Arabia. g.algrain@uoh.edu.sa

This is an open-access article distributed under the terms of the Creative Commons Attribution-Non Commercial-Share Alike 4.0 License, which allows others to remix, tweak, and build upon the work non commercially, as long as the author is credited and the new creations are licensed under the identical terms.

**How to cite this article:** Fadulemulla IA, AlShammari AD, ElHussein N, Seifeldin SA, AlShammari QT. Evaluation of the Anterior Cruciate Ligament Injury of Knee Joint Using Magnetic Resonances Imaging. Arch Pharm Pract. 2023;14(1):56-61. <https://doi.org/10.51847/LxagvnoXIS>

the joint. Clinical examination is used to diagnose the condition, and magnetic resonance imaging is used to verify it. The image shows the position and severity of the tear, as well as the existence of any concomitant injuries [4].

A rupture or sprain of the anterior cruciate ligament (ACL), one of the tough tissue ligaments that connect the femur to the shin bone, is known as an anterior cruciate ligament injury (ACL) (tibia). ACL injuries are common in sports such as football, basketball, soccer, and downhill skiing, which entail rapid pauses or changes in direction as well as leaps and landings. When an ACL injury happens, many patients hear or feel a "pop" in their knee. Furthermore, the knee may enlarge or become unsteady, making it difficult to bear weight.

In the occurrence of a tear, the anterior cruciate ligament of the knee, which is totally within the joint and is responsible for rotational and forward stability, cannot repair. ACL tear usually requires a solid injury, usually a sprain. Knuckle-rotational gyration [5].

An injury accompanies about 50% of cruciate ligament rupture to the meniscus or other ligaments or an injury to the articular surface, which can be diagnosed clinically and by magnetic resonance imaging [6].

Without needing an incision, a knee MRI examination combines magnets and radio waves to take images from the inside of the knee. It is possible to do it on any part of the body. A knee MRI shows the knee and the surrounding areas. An MRI allows your doctor to see the soft tissues and bones in the body. This permits him to check at parts of the knee that may have been injured or damaged during physical exercise. The examination can also produce detailed images of the bones, cartilage, tendons, muscles, vasculature, and ligaments in the knee. Furthermore, an MRI produces superior contrast images than any other test [7].

In combination with conventional x-ray, MRI is usually the best choice for examining the body's major joints like the knee [7]. The examination is performed to diagnose or evaluate knee pain, weakness, swelling, or bleeding in the tissue and around the joint. Damaged cartilage, meniscus, ligament, or tendons. Unlike the x-ray, which takes an image of the bone, a knee MRI makes it easy to see other structures [7].

Anterior cruciate ligament tears are a prevalent knee injury that can happen in a variety of circumstances. With the revolution of diagnostic imaging, MRI is considered one of the superior imaging modalities in the case of ACL injuries. The research emphasizes the importance of MRI in the diagnosis of ACL abnormalities in ACL injury of the knees. Furthermore, the study looks into many forms of injuries.

## MATERIALS AND METHODS

### *Population and Sampling of the Study*

Patients with meniscal and anterior cruciate ligament injuries were included in the study. A total of 92 sportsmen. Data from the patients were gathered from the king Salman Specialist Hospital and King Khaled Hospital in the Hail region in Saudi Arabia.

### *Inclusion Criteria*

This study includes patients aged between 20 and 80. Patients who have been injured recently during the last three months are also included.

### *Exclusion Criteria*

Patients who have not undergone surgery to fix the injury are part of the conducted study.

### *Area of the Study*

The study was conducted in the Hail region in Saudi Arabia at King Salman Specialist Hospital and King Khaled Hospital.

### *Equipment*

Both 1.5 and 1 Tesla MRI units (Siemens Medical Systems) examined patients with clinically suspected knee joint abnormalities.

### *MRI Examination*

The patient was supine on the MRI table, feet first, with both legs stretched. To aid preserve this position, the foot is twisted medially to center the patella between the femoral condyles, or sandbags are placed against the ankle. The coil on the knee should be in close proximity to the joint. 2.5 cm below the apex of the patella, across the joint in a straight line. There are four basic protocols including anatomy-defining sequences such as T1, GRE, and proton density or fluid-sensitive sequences such as inversion recovery and fat saturation. Although there is overlap between them (T1 post-contrast \_intra articular or intra venoms) are also used for the definition of anatomy and detection of pathology respectively

### *Design of Study*

The study used a retrospective cross-section study approach to demonstrate the objectives of the study in addition to a longitudinal case study to achieve the primary purpose of the study.

### *Duration of the Study*

The study was done from January 2022 to May 2022, starting from the approval of this proposal until the final submission of the thesis.

### *Data Analysis*

The study's data were analyzed using the SPSS program, which was also utilized for data analysis in the thesis.

### *Ethical Considerations*

Approval was obtained from the University of Hail, a written and signed consent was obtained from each patient before the investigation is made mentioning.

**RESULTS AND DISCUSSION**

**Table 1.** Demonstrate the distribution of patients according to age groups

	Frequency	Percent
Valid	20-40	8 8.7
	41-60	57 62.0
	61-80	27 29.3
	Total	92 100

Table show that the frequencies of patients admitted to the radiology department with suspicion of knee abnormalities in the age group ranged from 41-60 years old with a percentage equal to 62%

The male more frequently complained of knee problems with a percentage equal to 74% (80.4%) and frequency in female 18 (19.6%).

**Table 2.** Demonstrate the patients compiling admitted for Knees MRI

	Frequency	Percent
Valid	Chronic Pain	4 4.3
	History Sport Injury	1 1.1
	Knee Injury	29 31.5
	LT knee locking	1 1.1
	Pain	15 16.3
	Rapture of ACL	1 1.1

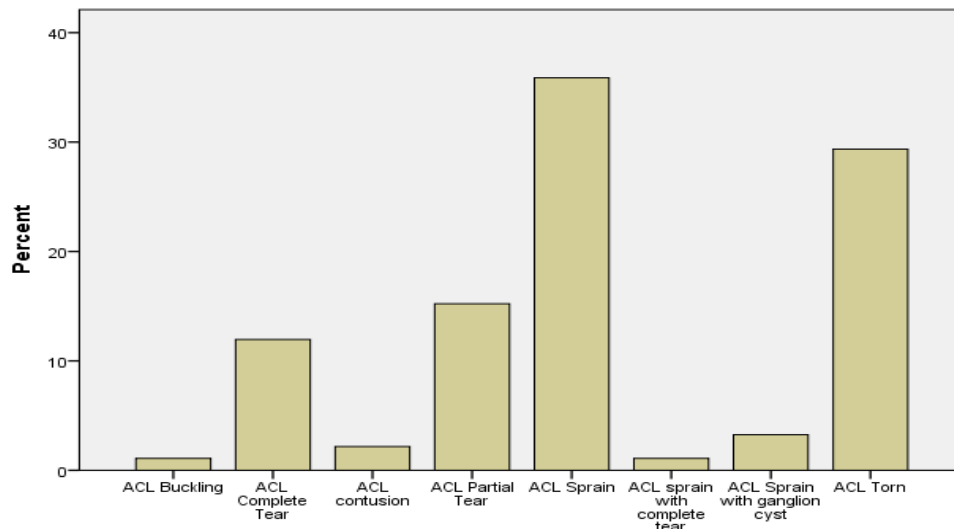
Right Knee Locking	1	1.1
Sport Trauma	14	15.2
Swelling	7	7.6
Trauma	8	8.7
Torsion	2	2.2
Twisting Knee Injury	9	9.8
Total	92	100

Regarding **Table 2** our results demonstrate that the most common signs and symptoms in patients compiling of knee problems are knee injuries, pain, and sports trauma respectively, 29(31.5%), 15(16.3%), and 14 (15.2%) respectively.

Regarding the effective side our results show that out of 92 patients complaining of knee joint problems, the right side is the most common effective side 50 (54.3%), left side 42 (45.7%).

**Table 3.** Demonstrate the MRI findings in the ACL

	Frequency	%	Valid %	Cumulative %
ACL Buckling	1	1.1	1.1	1.1
ACL Complete Tear	11	12.0	12.0	13.0
ACL contusion	2	2.2	2.2	15.2
ACL Partial Tear	14	15.2	15.2	30.4
ACL Sprain	33	35.9	35.9	66.3
ACL sprain with complete tear	1	1.1	1.1	67.4
ACL Sprain with ganglion cyst	3	3.3	3.3	70.7
ACL Torn	27	29.3	29.3	100.0
Total	92	100.0	100.0	



**Figure 1.** Shows the findings in the ACL injury

Most patients in this study were diagnosed with ACL sprain 33 (35.9%) followed by ACL torn 27(29.3%). Moreover, 25 (25.2%) patients were diagnosed with ACL tears out of these

25 patients 14 (56%) were diagnosed with partial tears and 11 (44%) were diagnosed with a partial tear (**Table 3, Figure 1**).

**Table 4.** Demonstrate the distribution of MRI findings in the ACL injury according to gender

		Findings													
		ACL contusion	ACL partial tear	ACL sprain	ACL Sprain	ACL sprain	ACL sprain complete tear	ACL Sprain with ganglion cyst	ACL sprain	ACL tear	Buckling of ACL	Complete tear of ACL	Partial ACL Chronic tear	Torn ACL	Total
Gender	F	1	1	7	2	0	0	0	0	0	0	2	2	3	18
	M	1	1	19	2	1	1	3	2	3	1	9	7	24	74
Total		2	2	26	4	1	1	3	2	3	1	11	9	27	92

When we compared the findings in MRI images with gender our results found that the males were more affected than

females. Furthermore, ACL sprain ACL tore, partial and complete tears affect the male more than females (**Table 4**).

**Table 5.** Demonstrate the distribution of MRI findings in the ACL injury according to age groups

		Findings													
		ACL contusion	ACL partial tear	ACL sprain	ACL Sprain	ACL sprain	ACL sprain complete tear	ACL Sprain with ganglion cyst	ACL sprain	ACL tear	Buckling of ACL	Complete tear of ACL	Partial ACL Chronic tear	Torn ACL	Total
Age	20-40	0	0	3	0	1	0	0	0	0	0	1	2	1	8
	41-60	2	1	14	3	0	0	1	2	3	0	8	5	18	57
	61-80	0	1	9	1	0	1	2	0	0	1	2	2	8	27
Total		2	2	26	4	1	1	3	2	3	1	11	9	27	92

**Table 6.** Demonstrate the distribution of MRI findings in the ACL injury according to the affected side

		Findings													
		ACL contusion	ACL partial tear	ACL sprain	ACL Sprain	ACL sprain	ACL sprain complete tear	ACL Sprain with ganglion cyst	ACL sprain	ACL tear	Buckling of ACL	Complete tear of ACL	Partial ACL Chronic tear	Torn ACL	Total
Side of the knee	Left	1	1	14	2	1	0	2	2	2	0	4	3	10	42
	Right	1	1	12	2	0	1	1	0	1	1	7	6	17	50
Total		2	2	26	4	1	1	3	2	3	1	11	9	27	92

The incidence percentage of findings based on age groups were 8(8.69%), 57(61.95%) and, 27 (29.34%) for age ranges 20-40 years, 41-60 years, 61-80 years respectively.

In the current study, we noticed that patients aged 41-60 years presented with higher incidence rates of knee abnormalities 57 (61.95%) when compared with the other age groups (**Table 5**).

Moreover, the incidence percentage of findings based on the effaced side we noticed that the right side is the most commonly affected (**Table 6**).

To the best of my knowledge, patients with anterior cruciate ligament injuries were regularly referred for knee MRI examinations in most institutes, which is also correct for our institute.

This study aimed to evaluate the articular cartilage ligament injury of the knee joint using magnetic resonance imaging in patients who came to the radiology department at king Salman Specialist Hospital and King Khaled Hospital in the Hail region in Saudi Arabia. A total number of 92 patients who admitted for MRI examination with a knee injury. From the results plotted in chapter four in the form of tables and figures, 92 patients were distributed in a total of three age groups. The most frequent 57 patients fall under the category of 41 to 60 years (**Table 1**), these findings go in contrast with Khan, *et al.* [8], where they found that most patients were between the ages of 35-40 years.

Regarding the gender of patients, Moran, *et al.* [9] stated that A total of 221 MLKIs were identified, of which 32 (14.5%) had an intact ACL (87.5% male; mean age of  $29.9 \pm 8.6$  years) and were included. In our research, most of the cases were males with a frequency of 74 patients and 18 patients for females which indicates that males are more affected by such lesions (**Table 2**).

The incidence of the meniscus and anterior cruciate ligaments rate in our study was similar to the results reported by Salah Eldeen Dafalla *et al.* [10]. The incidence of anterior cruciate ligament injuries and other ligament injuries in the Saudi community in Jeddah.

Indications for knee MRI differ from one patient to another. Most patients complained of knee injury with a frequency of 29 patients. On the other hand, knee pain which seconds most frequency of 15 patients complaining of it. History of sports injury, LT knee locking, RT knee locking, and rapture of ACL reported 1 patient for each which is the lowest frequency (**Table 3**).

Since the knee is a bilateral organ, and when evaluating the most affected side the results showed that the right knee is the most affected side with a frequency of 50 patients (**Table 4**). Wang (2021), [11], got a similar finding, there were seven cases of the left knee and 12 cases of the right knee; all patients had sports injuries.

For the knee injuries, the MRI findings that were reported, ACL sprain reported the highest frequency, which was 33 patients followed by torn ACL with a frequency of 27 patients.

ACL sprain complete tear and buckling of ACL reported the lowest frequency which was 1 patient for each (**Table 5**).

These findings support the findings of Young *et al.* [12] who state in their research that at least part of the ALL was visualized in more than 95% of MRIs despite the degree of ACL integrity. It also showed that the mean rate of identifying an ALL injury in the setting of a complete ACL tear on MRI was 53.05% with the minimal inter-rater agreement between radiologists.

When correlating the MRI findings and patients' gender, 7 female patients had ACL sprains whereas male patients were more with a frequency of 19 male patients. 24 male patients had Torn ACLs whereas females had only 3 patients. From the plotted results, we recognized that Our MRI statistics indicate that men were more likely than females to be affected by the injury (**Table 6**).

In the correlation of age group and MRI findings. Most findings are in the age group from 41 to 60 years old with a frequency of 57 patients. 18 patients of which had torn ACLs and 14 patients had ACL sprains. In second place comes the age group from 61 to 80 years old with a frequency of 27 patients 9 patients of which had ACL sprain (**Table 7**).

As mentioned previously, MRI findings were more on the right side with a frequency of 50 patients. 17 patients of which had torn ACLs. ACL sprain recorded nothing on the right side. 14 patients complained of ACL sprain on the left side (**Table 8**).

Such findings could be compared to a cross-section study of 282 patients that reviewed the findings obtained during an MRI scan of the knee, They determined that the right knee was more affected than the left in about (51.4%) of the cases [9, 13].

## CONCLUSION

MRI has a high sensitivity for the detection of ACL, meniscal, and articular cartilage in patients with knee injuries, and so plays a major role in determining the disease's diagnosis and management. ACL Torn and sprain were more prevalent in anterior cruciate ligament deficient participants. The high frequencies of the disorders were observed in age groups 21-40 years old. Further studies were recommended.

**ACKNOWLEDGMENTS:** The authors thanks the radiological staff in the radiology departments of the king Khalid and king Salman hospitals.

**CONFLICT OF INTEREST:** None

**FINANCIAL SUPPORT:** None

**ETHICS STATEMENT:** This study was approved from University of Hail and written informed consents were gotten from all patients

## REFERENCES

1. Caparrós T, Alentorn-Geli E, Myer GD, Capdevila L, Samuelsson K, Hamilton B, et al. The Relationship of Practice Exposure and Injury Rate on Game Performance and Season Success in Professional Male Basketball. *J Sports Sci Med.* 2016;15(3):397-402.

2. Awwad GEH, Coleman JH, Dunkley CJ, Dewar DC. An Analysis of Knee Injuries in Rugby League: The Experience at the Newcastle Knights Professional Rugby League Team. *Sports Med Open*. 2019;5(1):33.
3. Miller MA, Zachary JF. Mechanisms and morphology of cellular injury, adaptation, and death. *Pathologic basis of veterinary disease*. 2017:2.
4. Chinn L, Hertel J. Rehabilitation of ankle and foot injuries in athletes. *Clin Sports Med*. 2010;29(1):157-67.
5. Yeager CR. Anterior Cruciate Ligament (ACL): Causes of Injury, Adverse Effects and Treatment Options. *Nova Biomedical Books*; 2010.
6. Simon D, Mascarenhas R, Saltzman BM, Rollins M, Bach BR Jr, MacDonald P. The Relationship between Anterior Cruciate Ligament Injury and Osteoarthritis of the Knee. *Adv Orthop*. 2015;2015:928301.
7. Knee MRI. 2022 report. Available from: <https://www.radiologyinfo.org/en/info/kneemr>
8. Khan MA, Khan MU, Ullah Z, Ullah A, Gul J. Evaluation of Knee Joint Injuries with Magnetic Resonance Imaging (MRI) and Correlation with Arthroscopy. *Pakistan J Med Health Sci*. 2022;16(09):829.
9. Moran J, Schneble CA, Katz LD, Jimenez AE, McLaughlin WM, Vasavada K, et al. Over One-Third of Patients with Multi-Ligament Knee Injuries and An Intact Anterior Cruciate Ligament Demonstrate Medial Meniscal Ramp Lesions on Magnetic Resonance Imaging. *Arthroscopy*. 2022;38(8):2472-9.
10. Dafalla SE, Bokhari YA, Yazbik RS, Ali AS, Sheikh KH. Prevalence of Anterior Cru-ciate Ligament Injury and other Ligament Injuries among the Saudi Community in Jeddah City, Saudi Arabia. *Int J Radiol Imaging Technol*. 2020;6(1):062.
11. Wang M. Medical Imaging Diagnosis of Anterior Cruciate Ligament Injury Based on Intelligent Finite-Element Algorithm. *J Healthc Eng*. 2021;2021:6073757.
12. Young BL, Ruder JA, Trofa DP, Fleischli JE. Visualization of Concurrent Anterolateral and Anterior Cruciate Ligament Injury on Magnetic Resonance Imaging. *Arthroscopy*. 2020;36(4):1086-91.
13. Shevchenko YS, Plohova DP, Bulakhova IN, Mishvelov AE, Kubalova ME, Badriev GB, et al. Experience of carrying out magnetic resonance imaging with the use of specialized protocols and programs computer post-processing. *Pharmacophore*. 2020;11(2):77-81.