

Roles for *Taraxacum officinale* and Vitamins (C, K) on Bone Formation and Resorption Heparin-Induced in Rats

Amani Mohammad Alfaifi¹, Manal Abdulbari Tashkandi¹, Jehad Mustafa Yousef^{1*}

¹Department of Biochemistry, College of Science, University of Jeddah, KSA.

Abstract

The present research determined how the anticoagulant drug Heparin caused osteoporosis in rats and how *Taraxacum officinale* and/or vitamins can prevent it (C, K). Fifty female Wester albino rats were used in the 30-day study. They were placed into five groups. In the heparin-treated group, bone-specific alkaline phosphatase (ALP), osteocalcin (CO), deoxypyridinoline (DPD), and tartrate-resistant acid phosphatase (TRAP) were significantly increased in contrast to the control group. *Taraxacum officinale* and/or Vitamins (C, K) co-treatment of rats receiving heparin significantly reversed the declines in the examined parameters and the histomorphologic bone tissue images. In conclusion, the data showed that *Taraxacum officinale* and/or Vitamins (C, K) could protect the bone tissues from the damaging impact of heparin, which was more pronounced in rats treated with the combination of the two agents *Taraxacum officinale* and Vitamins (C, K). The current study may support the utilization of this combination as a promising therapy to alleviate the adverse of the anticoagulant heparin.

Keywords: *Taraxacum officinale*, Osteoporosis, Heparin, Osteoblast, Osteoclast

INTRODUCTION

Bone is made up of four different types of cells: Osteocytes, osteoblasts, bone lining cells, and osteoclasts [1]. Quiescent, revitalizing, resorption, creation, and mineralization are the five stages of bone's remodeling [2]. Bone matrix products are produced by osteoblasts as their main function (collagen types I and V, proteoglycans sialoprotein and osteopontin) [3] and osteoclasts are enormous cells that arise from hematopoietic stem cells in bone marrow in response to the number of stimuli, including macrophage colony-stimulating factor (M-CSF) [4] which osteocytes and osteoblasts both release, as well as receptor activator of nuclear factor kappa-B (RANK) ligand [5]. M-CSF stimulates proliferation and inhibits apoptosis via attaching to the osteoclast's tor receptor. RANKL is a significant element that binds to its receptor RANK and promotes osteoclastogenesis in osteoclast precursors [6]. By binding to RANKL and blocking the RANK/RANKL interaction, osteoprotegerin (OPG), a substance made by osteoblasts, inhibits osteoclastogenesis [7]. Consequently, the RANKL/RANK/OPG system is a crucial osteoclastogenesis regulator [4].

Numerous medications can impact bone metabolism. Heparin, warfarin, cyclosporine, and glucocorticoids are a few examples, the anticoagulant drug heparin is currently the most widely used worldwide [8]. Anticoagulants are widely used to treat thromboembolic cases and to prevent stroke. Some of the information on their effects on bone health is scarce, but in the case of others (heparins), it is strong enough to advise caution while using them in those who are at risk of osteoporosis. Osteoprotegerin (OPG), a RANKL decoy

receptor released by osteoblasts, inhibits osteoclast production and activation, which are both triggered by the receptor activator of NFkappaB ligand (RANKL) on osteoblasts [9].

Taraxacum officinale is a plant in the *Asteraceae Compositae* family [7]. Indeed, It includes a wide range of phytochemicals, whose biological effects are being researched in several fields related to human health. Numerous biological effects are produced by *Taraxacum officinale* and its components, which contain antioxidant and anti-inflammatory characteristics [10]. To prevent osteoporosis and lower the risk of fractures, non-pharmacological management is also important for optimal osteoporosis treatment, even though pharmaceutical treatment is the most popular. The herb *Taraxacum officinale* is high in minerals such as iron, magnesium, sodium,

Address for correspondence: Jehad Mustafa Yousef, Department of Biochemistry, College of Science, University of Jeddah, KSA. Jmyousef@uj.edu.sa

This is an open-access article distributed under the terms of the Creative Commons Attribution-Non Commercial-Share Alike 4.0 License, which allows others to remix, tweak, and build upon the work non commercially, as long as the author is credited and the new creations are licensed under the identical terms.

How to cite this article: Alfaifi AM, Tashkandi MA, Yousef JM. Roles for *Taraxacum officinale* and Vitamins (C, K) on Bone Formation and Resorption Heparin-Induced in Rats. Arch Pharm Pract. 2023;14(2):82-91. <https://doi.org/10.51847/vrJlyCiYi>

calcium, silicon, copper, phosphorus, and zinc as well as vitamins (A, C, D, E, and B), inositol, and lecithin [11], which also contain inulin and fructooligosaccharides, can increase calcium absorption, limit bone resorption later in life, and suppress bone loss during growth [12].

Vitamin C (VC) has a significant impact on the skeletal system; its potential effects on gene transcription, deoxyribonucleic acid (DNA), and osteoblast maturation range from suppressing osteoclast activity and encouraging osteoblast maturation by enhancing collagen type I production, and histone methylation. Along with treating the condition, effective osteoporosis prevention is crucial to halting the disease's progression and reducing related fractures. However, according to some data, vitamin C may help prevent osteoporosis and fractures [13]. VC is an important cofactor for lysine and proline hydroxylation, which are required for collagen fibril cross-linking in bone. Increases the activation of alkaline phosphatase, which is an indicator of osteoblast formation [14]. Is implicated in osteoblastogenesis through PPAR-g expression and osteoclastogenesis through RANKL expression [15].

Vitamin K (liposoluble vitamin) contains a variety of bone-specific modes of action [16]. Gamma-carboxyglutamic acid is formed when the enzyme gamma-glutamyl carboxylase carboxylates glutamic acid (Glu) residues in vitamin K-dependent proteins (Gla). Matrix Gla protein, periostin, and osteocalcin are examples of vitamin K-dependent proteins found in bone (or bone Gla protein). During the mineralization phase of bone, osteoblasts produce osteocalcin, which binds to calcium ions and hydroxyapatite crystals to govern their size and structure [17]. Vitamin K is crucial for bone health through methods other than gamma-carboxylation. In addition to inhibiting bone production, it can control the transcription of osteoblastic markers' genes [18].

The goal of the current study was to determine whether a natural plant called *Taraxacum officinale*, which is available in the Kingdom of Saudi Arabia, could prevent osteoporosis and its complications, such as oxidative stress, inflammation, and apoptosis, in female rats being treated with heparin. Vitamins C and K were also compared to the potential prophylactic effects of this plant.

MATERIALS AND METHODS

Chemicals

Heparinol, heparin sodium 5,000 I.U./ml injectable or infusion solution concentrate, Ain Medicare Sdn Bhd, Malaysia, Vitamin C (ascorbic acid), manufactured for Doctor's Best, Inc. Tustin, California, 92780 USA, Vitamin K (phytonadione) tablets, 500 mcg by Source Naturals and *Taraxacum officinale* plant collected in spring from southern Saudi Arabia were used in this study. Kits from MyBioSource

were obtained to quantitatively determine various characteristics (San Diego, United States).

Animals and Treatment

In this study, fifty adult female albino rats (180-200gm) were used, from the Faculty of Pharmacy at King Abdulaziz University. Animals were housed under controlled conditions (18-23°C, humidity 40-60%, and the usual cycle were 14 hours of light and 10 hours of darkness). Making sure there were no lights on and that neither scientists nor technicians visit the mouse room while it is dark. Diet: The fat content ranges between 4% and 11%. Water: Water should always be available. Rat handling was done following the expectations of the pharmacy faculty at King Abdulaziz University. Seven days were given to the animals to acclimate. The creatures were split into five groups of ten rats apiece:

- **Group I:** Normal rats that will be treated orally with D.W. only for 30 days.
- **Group II:** Rats will be treated by subcutaneous injection of unfractionated heparin (0.001 mg/ kg) 30-day period [19].
- **Group III:** Rats will be co-administered orally with *Taraxacum officinale* water extract dose (2.4 mg/ kg) along with heparin injection for 30 days [20].
- **Group IV:** Rats will be co-administered orally with vitamin K (50 mg/kg) [21] and vitamin C (200 mg/ kg) [22] with heparin injection for 30 days.
- **Group V:** For 30 days, rats will also get heparin and the oral mixture of *Taraxacum officinale*, vitamins C and K.

Extraction of *Taraxacum officinale* leaves, collected fresh leaves of *Taraxacum officinale* were, frozen for ten hours at -80 °C, then moved to a lyophilizer (vacuum, freeze at -65 °C), where they were dried completely for two days. A plastic bag was used to crush the dried plant, which was then pulverized, sieved, and weighed. High-performance liquid chromatography (HPLC) was used to separate the weight of 6.37 g of the powdered dry plant from 150 ml of methanol, 150 ml of methanol, 150 ml of methanol, stopped, shaken for 5 minutes, and then filtered over a 0.45 Nylon membrane while under vacuum. The solvent was eliminated using a rotary evaporator at 35 °C, and the clear filtrate was then transferred to another clean, dry, 250 ml round flask. The residue that was collected weighed 0.728 g and was stored at -20 °C until use.

$$\% \text{ Yield} = (0.728 / 6.37) \times 100 = 11.43\%, \text{ g/g\%} \quad (1)$$

[20]

Biochemical Analysis Serum Analysis

Serum bone formation markers bone-specific alkaline phosphatase (ALP), osteocalcin (OC), and bone resorption markers deoxypyridinoline (DPD) and tartrate-resistant

phosphatase (TRAP) using an automated analyzer, were assessed as biomarkers of bone osteoporosis damage.

Histopathological Studies

The histopathological changes of bone in different experimental heparin groups were examined using bone tissues. Samples of bone tissue were taken, and they were fixed in 4% formaldehyde for 24 hours. They were then gradually dehydrated in ethyl alcohol, cleaned in xylene, and set in paraffin. For staining, paraffin blocks were mounted on glass slides after being sliced with a microtome at 4-5 micrometers. Hematoxylin and eosin were used to stain the sections (H&E) [23].

Statistical Analysis

To statistically assess the data, the results for the various experimental groups were compared to the values of the individual normal groups. The outcomes are presented as mean + SD. Significant differences between groups were investigated using one-way analysis of variance (ONE-WAY ANOVA) and post-Hoc least significant difference (LSD). For an analysis of variance (ANOVA), 0.05 was the threshold for significance. Version 23 of the statistical package for the social sciences (SPSS) was used to conduct the statistical analysis.

RESULTS AND DISCUSSION

Effect of *Taraxacum Officinale* and Vitamins (C, K) on Bone Formation Indices in Heparin-Treated Female Rats

Table 1 and **Figures 1 and 2** respectively, show the serum levels of bone on osteoporosis parameters, Bone-specific alkaline phosphatase (ALP), and Osteocalcin (OC). The

impact of the combination of *Taraxacum officinale*, Vitamin C, and K with heparin-treated rats was the most potential prophylactic impact on the levels in relation to the treatment with each agent lonely.

As compared to the normal group (G1) after 30 days. A very highly significant decrease was found in serum levels of ALP (u/l), while a very highly significant increase in OC (ng/ml) in G2 ($P \leq 0.001$). Non-Significant decrease ALP (u/l), a highly significant decrease of OC (ng/ml) ($P \leq 0.01$) in G3. A very highly significant decrease was found in serum levels of ALP (u/l), but a very highly significant increase in G4 ($P \leq 0.001$). Was found a non-significant increase in serum levels of ALP (u/l), but a non-significant decrease of OC (ng/ml) in G5.

When compared to heparin treated group (G2) in 30 days, A very highly significant increase was found in serum levels of ALP (u/l), but a very highly significant decrease of OC (ng/ml) ($P \leq 0.001$) in G 3,4,5 ($P \leq 0.001$).

When comparing the group co-administered heparin and orally with *Taraxacum officinale* water extract (G3) for 30 days. A very highly significant increase was found in serum levels of ALP (u/l), but a very highly significant decrease of OC (ng/ml) ($P \leq 0.001$) in G 4. Was found non-significant decrease in serum levels of ALP (u/l), and a significant increase of OC (ng/ml) ($P < 0.05$) in G5.

When compared to the combination group (G5) co-administered heparin and orally with *Taraxacum officinale* water extract and vitamin C and K for 30 days, A very highly significant decrease was found in serum levels of ALP (u/l), but a very highly significant increase in serum levels of OC (ng/ml) ($P \leq 0.001$) in G4.

Table 1. Effect of *Taraxacum officinale* and vitamins (C, K) on bone formation indices in heparin-treated female rats

Groups	Parameters	ALP	Change percentage	OC	percentage
G1		52.80±9.94		12.13±2.45	
G2		a*** 144.25±16.50	173%	a*** 45.75±4.86	277%
G3		b*** 49.70±8.56	-6%	a**,b*** 8.36±1.49	-31%
G4		a***,b***,c*** 78.70±10.36	49%	a***,b***,c*** 17.20±1.80	42%
G5		b***,d*** 49.50±6.02	-6%	b***,c*,d*** 11.38±2.27	-6%

Values are expressed as mean ±SD of 10 rats. **** $P \leq 0.001$, *** $P \leq 0.01$, compared with the control group(G1). b*** $P \leq 0.001$, compared with the heparin-treated group(G2). c*** $P \leq 0.001$, c $P < 0.05$ compared with the heparin+ taraxacum (G3). d*** $P \leq 0.001$, compared with the heparin+ Vit (C, K) (G4).

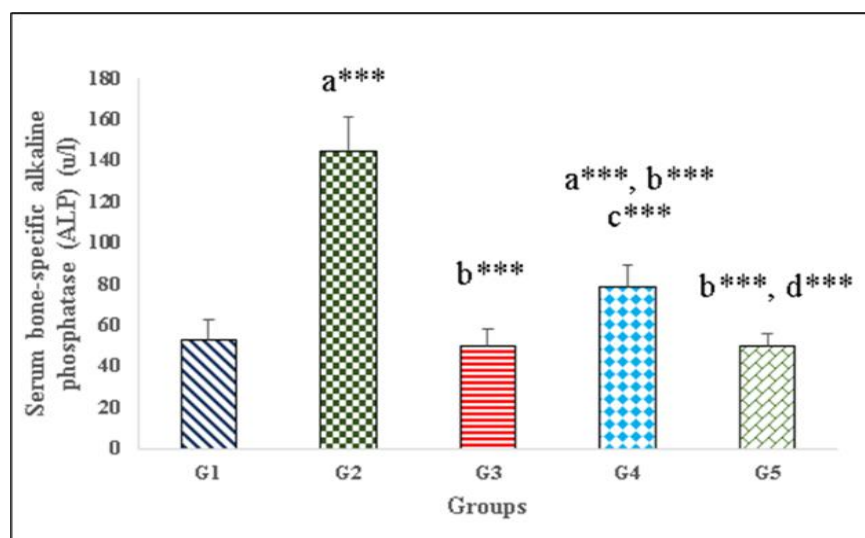


Figure 1. Effect of serum bone-specific alkaline phosphatase activity (ALP) after 30 days. Mean±SD: stander diffusion. G1 (normal group), G2 (Unfractionated heparin), G3 (Unfractionated heparin + *Taraxacum officinale* water extract), G4 (Unfractionated heparin + Vitamin C + Vitamin K), and G5 (Unfractionated heparin + *Taraxacum officinale* water extract + Vitamin C + Vitamin K). ^aP≤0.001 very highly significant increase when compared with G2 and G4. ^bP≤0.001 very highly significant decrease when compared with G2. ^cP≤0.001 very highly significant increase when compared with G4. ^dP≤0.001 very highly significant decrease when compared with G5.

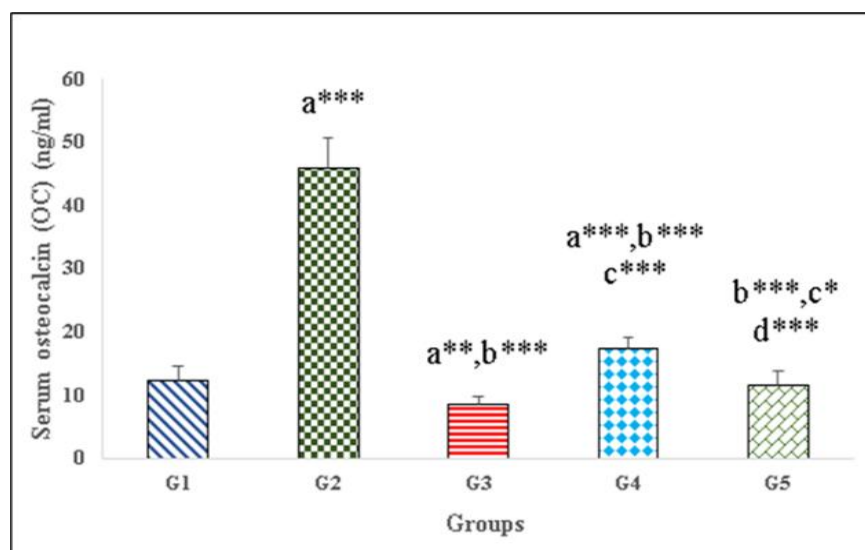


Figure 2. Effect of serum osteocalcin (OC) after 30 days. Mean±SD: stander diffusion. G1 (normal group), G2 (Unfractionated heparin), G3 (Unfractionated heparin + *Taraxacum officinale* water extract), G4 (Unfractionated heparin + Vitamin C + Vitamin K), and G5 (Unfractionated heparin + *Taraxacum officinale* water extract + Vitamin C + Vitamin K). ^aP≤0.001 very highly significant increase when compared with G2 and G4, ^aP≤0.01 highly significant decrease when compared with G3. ^bP≤0.001 very highly significant decrease when compared with G2. ^cP≤0.001 very highly significant decrease when compared with G4, ^cP<0.05 significant increase when compared with G5. ^dP≤0.001 very highly significant increase when compared with G5.

Effect of *Taraxacum Officinale* and Vitamins (C, K) on Bone Resorption Indices in Heparin-Treated Female Rats

Table 2 and **Figures 3** and **4** respectively, show the serum levels of bone on osteoporosis parameters deoxypyridinoline (DPD), and tartrate-resistant acid phosphatase (TRAP). The

impact of the combination of *Taraxacum officinale*, vitamin C, and K with heparin-treated rats was the most potential prophylactic impact on the levels in relation to the treatment with each agent lonely.

As compared to the normal group (G1) after 30 days. A very highly significant decrease was found in serum levels of DPD

(nM) and TRAP (ng/ml) in G2 ($P \leq 0.001$). Significant decrease of DPD (nM) ($P < 0.05$), while a non-significant decrease of TRAP (ng/ml) in G3. A very highly significant decrease was found in serum levels of DPD (nM) and TRAP (ng/ml) in G4 ($P \leq 0.001$). Was found a non-significant increase in serum levels of DPD (nM) and TRAP (ng/ml) in G5.

When compared to heparin treated group (G2) in 30 days, A very highly significant increase was found in serum levels of DPD (nM) and TRAP (ng/ml) in G 3,4,5 ($P \leq 0.001$).

When comparing the group co-administered heparin and orally with *Taraxacum officinale* water extract (G3) for 30 days A very highly significant increase was found in serum level of DPD (nM) and TRAP (ng/ml) ($P \leq 0.001$) in G4. Significant decrease of DPD (nM) ($P < 0.05$), while a non-significant decrease of TRAP (ng/ml) in G5.

When compared to the combination group (G5) co-administered heparin and orally with *Taraxacum officinale* water extract and vitamin C and K for 30 days, A very highly significant decrease was found in serum levels of DPD (nM) and TRAP (ng/ml) ($P \leq 0.001$) in G4.

Table 2. Effect of *Taraxacum* and vitamins (C, K) on bone resorption indices in heparin-treated female rats

Parameters	DPD	Change percentage	TRAP	percentage
Groups				
G1	23.46±5.27		4.02±0.86	
G2	a*** 85.13±7.51	2.63%	a*** 11.69±1.99	1.90%
G3	a*,b*** 27.88±6.25	0.19%	b*** 4.19±0.78	0.04%
G4	a***,b***,c*** 37.90±5.17	0.61%	a***,b***,c*** 8.33±1.65	1.07%
G5	b***,c*,d*** 21.81±3.98	-0.07%	b***,d*** 3.31±0.75	-0.18%

Values are expressed as mean ±SD of 10 rats. a*** $P \leq 0.001$, a* $P < 0.05$, compared with the control group (G1)

b*** $P \leq 0.001$, compared with the heparin-treated group (G2). c*** $P \leq 0.001$, c* $P < 0.05$ compared with the heparin+ *Taraxacum officinale* (G3). d*** $P \leq 0.001$, compared with the heparin+ Vit (C, K) (G4).

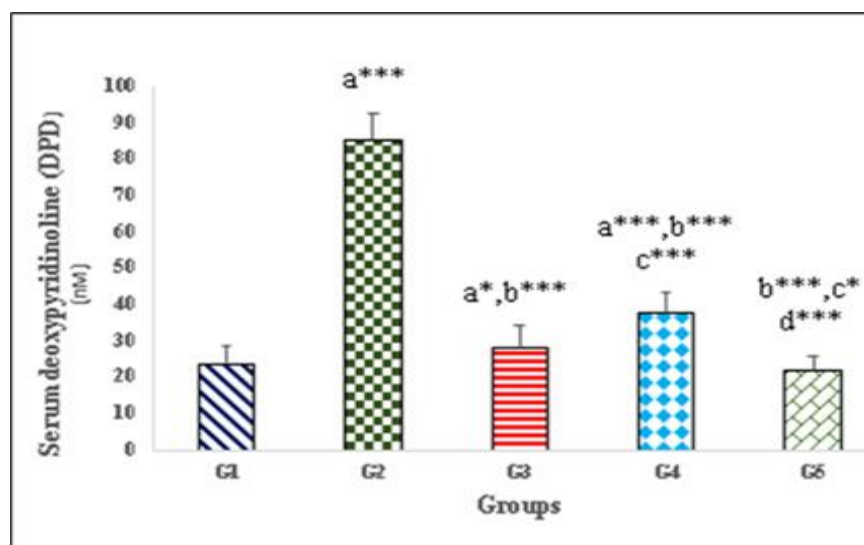


Figure 3. Effect of serum deoxyypyridinoline (DPD) levels after 30 days. Mean±SD: stander deviation. G1 (normal group), G2 (Unfractionated heparin), G3 (Unfractionated heparin + *Taraxacum officinale* water extract), G4 (Unfractionated heparin + Vitamin C + Vitamin K), and G5 (Unfractionated heparin + *Taraxacum officinale* water extract + Vitamin C + Vitamin K). * $P \leq 0.001$ very highly significant decrease when compared with G2 and G4, * $P < 0.05$ significant decrease when compared with G3. ^b $P \leq 0.001$ very highly significant increase when compared with G2. ^c $P \leq 0.001$ very highly significant increase when compared with G4, ^c $P < 0.05$ significant decrease when compared with G5. ^d $P \leq 0.001$ very highly significant decrease when compared with G5.

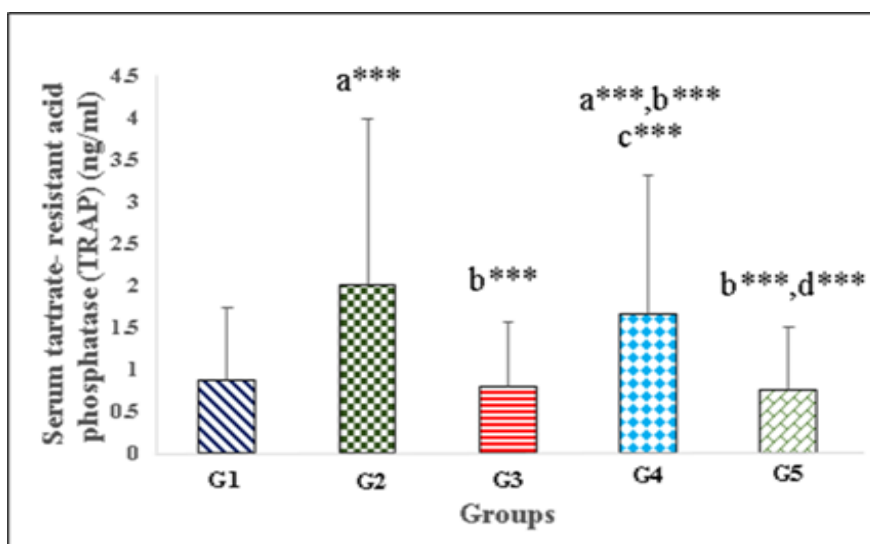
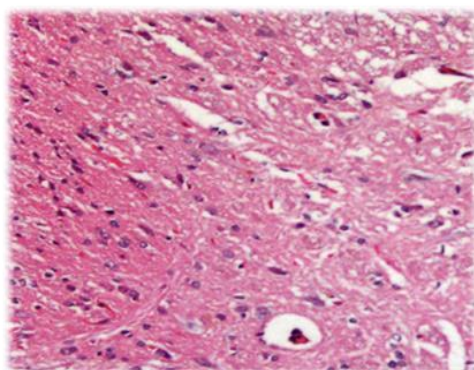


Figure 4. Effect of serum tartrate-resistant acid phosphatase activity (TRAP) after 30 days. Mean \pm SD: standard deviation. G1 (normal group), G2 (Unfractionated heparin), G3 (Unfractionated heparin + *Taraxacum officinale* water extract), G4 (Unfractionated heparin + Vitamin C + Vitamin K), and G5 (Unfractionated heparin + *Taraxacum officinale* water extract + Vitamin C + Vitamin K). aP \leq 0.001 very highly significant increase when compared with G1. bP \leq 0.001 very highly significant decrease when compared with G2. cP \leq 0.001 very highly significant decrease when compared with G4. dP \leq 0.001 very highly significant increase when compared with G5.

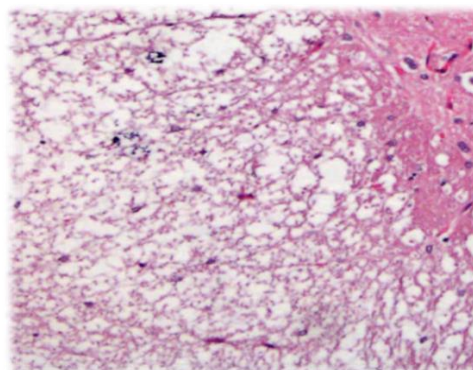
Histopathological Examination of Bone Tissue

In **Figure 5**, a light microscopic examination of hematoxylin and eosin (H&E) stained sections of rat bone in the control group showed the normal histological structure of bone with normal osteocytes. The bone cells most found in the bone tissue generally have protoplasmic projections and lacunae or small chambers. Cancellous bone Provides structural support and flexibility without the weight of compact bone. The medullary cavity is the hollow part of the bone that contains bone marrow and is made up of small, needle-like pieces of bone arranged like a honeycomb. In the group, negative control showed normal cancellous bone and normal spaces of medullary **a**.

Showed loss of cancellous bone, enlargement of the medullary spaces, and cortical porosity in bone sections of rats treated with heparin showed disfiguration of bone architecture, which was evident **b**. Bone sections of rats treated with heparin in concurrent with either dandelion extract only showed moderate loss of cancellous bone, enlargement of the medullary spaces, and cortical porosity **c**. As well as in bone sections of rats treated with vitamin (C, K) simultaneously with heparin, showed slight, of the medullary spaces, and cortical porosity **d**. Bone sections of rats treated with heparin simultaneously with dandelion extract and vitamins (C, K) showed normal cancellous bone and normal spaces of the medullary **e**.



a)



b)

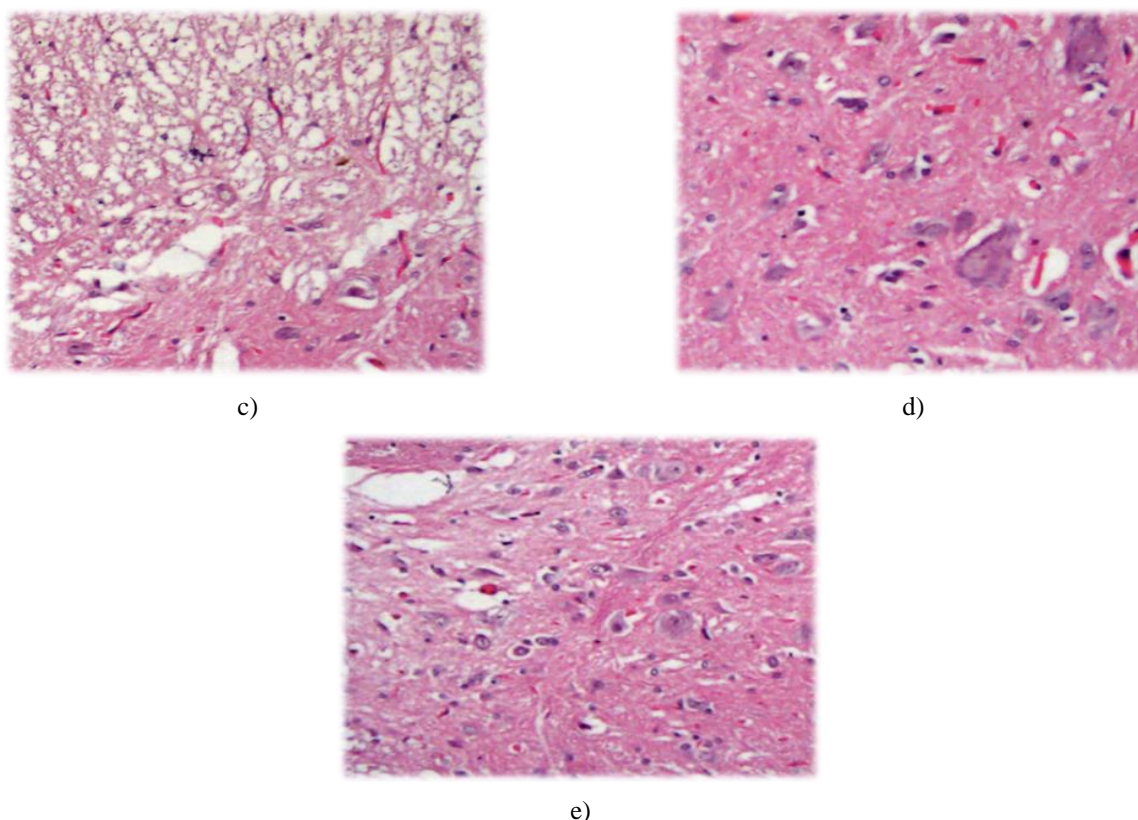


Figure 5. Light micrograph of rat bone sections in different control and heparin-treated groups. (a) Section of normal rat bone section, showing the general appearance of normal cancellous bone or trabecular and normal spaces of the medullary. (b) Section of rat bone section treated with heparin or positive control showed marker loss of cancellous bone, enlargement of the medullary spaces, and cortical porosity. (c) Section of rat bone section treated with heparin and administered orally with *Taraxacum officinale* water extract showed moderate loss of cancellous bone, enlargement of the medullary spaces, and cortical porosity. (d) Section of rat bone section treated with heparin and administered orally with vitamins C, and K, showed slight, of the medullary spaces, and cortical porosity. (e) Section of rat bone section was treated with heparin and administered orally with vitamins C, and K and administered orally with *Taraxacum officinale* water extract showed normal cancellous bone and normal spaces of the medullary (H&EX400).

Heparin is extensively used in the diagnosis, therapy, and prevention of thrombosis and embolism. Up to one-third of all patients getting long-term treatment, including bone mass loss and secondary osteoporosis, are thought to have osteoporosis, which is recognized as a significant side effect. A medicine may cause certain unpleasant consequences in addition to its necessary ones [24]. The use of unfractionated heparin (UFH) or low-molecular-weight heparin (LMWH) for an extended period causes bone loss and osteoporosis [25]. Clinical research and animal studies have demonstrated that long-term heparin use results in osteoporosis and bone loss, and a high cumulative heparin dosage has been associated with the progression of bone loss [26]. Heparin binds specifically to OPG and prevents it from interacting with RANKL on the osteoblastic membrane, hence promoting RANK-RANKL interaction and the activation of osteoclasts. Heparin-induced thrombocytopenia is frequently brought on by platelet-activating immunoglobulin G (IgG) antibodies (Abs) against platelet factor 4 (PF4) complexed with heparin (HIT) [27].

In clinical situations where preventing osteoporosis is more advantageous than treating it generally—which is the case generally—because preventing bone loss is easier than restoring lost density—great interest in folk medicine has recently been noted. As a result, it is urgent to find effective prophylactic agents to mitigate heparin-induced bone loss and osteoporosis. Without early diagnosis and treatment for osteoporosis, it may cause problems and raise the risk of fractures.

The goal of this study was to look into the potential prophylactic effects of *Taraxacum officinale* and vitamins C and K against the molecular components involved in, osteoporosis and its consequences, such as oxidative stress, inflammation, apoptosis, and fibrosis, in female rats treated with Heparin. The effects of *Taraxacum officinale* and both vitamins on histomorphological changes in rat bone intoxicated with heparin were also studied.

An increase in osteoclast activity and enhanced bone resorption capacity are the two main contributors to excessive bone disintegration [28]. Both a pathogenic role in osteoporosis, which is characterized by osteoclastic bone resorption, and an important physiological role for bone remodeling are played by osteoclasts [29].

A particular marker of bone resorption called DPD is produced in the blood during bone turnover as a result of collagen breakdown [30]. Previous research found that heparin was harmful to trabecular bone microstructures, which were higher in heparin-treated rats [31]. In the current study, serum DPD levels were found to be considerably higher. These results were supported by the fact that ovariectomized (OVX) rats with low testosterone levels had considerably greater DPD serum levels [32].

Osteoclasts that break down bone, inflammatory macrophages, and dendritic cells all have high levels of the enzyme tartrate-resistant acid phosphatase (TRAP). The blood contains the proteins TRAP 5a, which is derived from dendritic cells and macrophages, and TRAP 5b, which is derived from osteoclasts [33]. Osteoclasts are cells that are positive for the enzyme tartrate-resistant acid phosphatase (TRAP) and have more than three nuclei [34].

Osteocytes and osteoblasts both influence osteoclast formation, and it is now thought that osteocytes are crucial for osteoclast differentiation *in vivo* [35]. However, because osteocyte activity was challenging to investigate in the past, osteoblasts rather than osteocytes received a lot of attention when it came to osteoclast differentiation. Heparin's impact on the production of osteoclasts by osteoblasts is a finding that is comparable to our pit formation assay results, they found that heparin may boost the osteoclasts' capacity to resorb bone. They concluded that heparin medication promotes osteoblast-induced osteoclastic activity but not osteoclastogenesis as it had no impact on TRAP activity during their experiment. Heparin, on the other hand, was shown to increase the number of osteoclasts that were created, according to a different study. This finding suggests that heparin may encourage osteocyte-induced osteoclast development [34].

There are currently several biomarkers that can be used to accurately and sensitively measure the pace of bone growth. For instance, bone formation biomarkers like osteocalcin (OC) and bone-specific alkaline phosphatase (ALP) help provide an early assessment of osteoporosis when DXA BMD measurement is insufficient to make the diagnosis [36]. ALP activity is measured as an indicator of bone formation. An earlier study looked at the effect of heparin on alkaline phosphatase levels. Serum ALP levels in heparin-treated patients fell over time and continued to fall after treatment was stopped [37]. A time- and dose-dependent reduction in trabecular bone volume was also discovered by the histomorphometric study after UFH treatment. Heparin-

treated rats also had lower serum alkaline phosphatase levels and higher urinary pyridinoline levels (PYD) [38].

The 49-amino acid protein known as osteocalcin is also referred to as a bone gamma-carboxy glutamic acid-containing protein. OC is produced by hypertrophic chondrocytes, osteoblasts, and odontoblasts as they mature. Additionally, OC makes up the majority of non-collagenous proteins in bone and makes up about 2% of all the proteins in the human body. It is made by osteoblasts and is essential for metabolic regulation, homeostasis of calcium ions, and bone mineralization [39]. The rise in BMD during therapy with medicines that promote bone formation for osteoporosis is closely associated with the level of serum OC that was observed. For the assessment of the pace of bone production in osteoporosis. The biomarker serum OC has been identified as a specific indicator of osteoblast activity. Osteocalcin has been shown in numerous studies to be a crucial biomarker to examine the effectiveness of the medicine on bone growth. Serum OC, a biomarker of bone remodeling, may be useful in determining the degree of osteoporosis and forecasting the risk of fracture in the elderly, particularly in women [40].

Serum OC concentrations were found to be lower in heparin-treated rats in the studies. According to these studies, heparin severely affects bone growth. Thus, these results imply that heparin can increase osteoblast activity and that heparin's suppressive effect on the osteoblast's capacity to create bone is a significant contributing factor to bone fractures [41].

Overall, VC affects how bone matrix genes are expressed in osteoblasts, which in turn affects how much trabecular bone is produced. Recent research on the molecular mechanism of VC activities, as well as its direct impacts on target gene transcriptional regulation by modifying the activity of transcription factors and by epigenetically changing significant genes involved in skeletal development and maintenance, is described. Understanding the processes governing the uptake and metabolism of VC as well as the precise molecular pathways for VC activities in bone cells would allow for the creation of new therapeutic strategies or the modification of currently used ones to treat osteoporotic fractures [42].

Numerous studies have shown that the addition of VC to cultured osteoblast-like cells causes the early deposition of collagenous extracellular matrix and the activation of certain genes connected to the osteoblast phenotype, such as ALP, then, genes linked to the osteoblast phenotype, including alkaline phosphatase ALP, are activated [43]. The second prior study, VC, offers advantageous, significant, and potent antioxidants that have been used to treat a variety of ailments. These antioxidants promote decreased ALP activation and accelerate bone resorption caused by osteoclasts. The results of this investigation support the notion that systemic injection of VC can reduce osteoclast activation and inflammatory bone resorption, pointing to a potential new tactic for stopping periodontal bone loss and reducing osteoclast

activation. In the groups treated with antioxidants, VC consumption dramatically lowered ALP levels. The results of this investigation demonstrate that VC therapy greatly reduces local alveolar bone resorption [44].

The multipurpose VK has drawn attention to its effectiveness in accelerating bone turnover. By encouraging osteoblast development and raising the amount of several bone formation indicators, such as alkaline phosphatase, VK encourages bone formation. Additionally, VK inhibits osteoblast apoptosis and decreases osteoclast development as part of its anticatabolic effects to stop bone resorption [45].

The research indicates that the administration of VK to osteoblasts can raise the levels of OC and alkaline phosphatase activity in the cell media [46]. Alkaline phosphatase activity is inversely correlated with the production of the organic matrix and mineral component of bone, as well as the deposition of OC and hydroxyapatite in bone [17].

OC, a VK-dependent protein, is believed to have a significant impact on bone metabolism. OC is a VK-dependent protein that is virtually exclusively produced by osteoblasts in bone. Although its molecular function is unknown, the circulating antigen is frequently used as a marker for osteoblast activity [47].

Our findings imply that VK supplementation may lower bone turnover. The effects of VK are typically associated with decreased bone resorption and decreased presence of indicators. In line with earlier research, the effectiveness of VK therapy in OVX mice was confirmed by analyzing the bone resorption marker serum TRAP. In OVX-untreated mice, a substantial increase in serum TRAP activity was seen. However, between the OVX VK-treated animals and the similar controls, there was no statistically significant difference in serum TRAP activity. These results imply that supplementing VK may decrease bone turnover in OVX mice, but the underlying molecular mechanisms are still unknown [48].

Our findings support earlier research that found VC therapy significantly reduced TRAP levels. So, in line with earlier findings, VC lower levels of osteoclast-specific gene expression. Additionally, when compared to the negative control group, TRAP, RANK, and RANKL increased the number of osteoblasts and the osteoblast surface per bone surface while decreasing the number of osteoclasts and the osteoclast surface per bone surface [40]. A higher number of osteoclasts were also seen in the rat bones treated with OVX, which is consistent with past observations [36].

CONCLUSION

According to the current study, heparin therapy has the potential to cause osteoporosis. The combination of *Taraxacum officinale* and vitamins C, and K/or *Taraxacum*

officinale and vitamin C, resulted in prophylactic protection of bone tissue from the potential effect of heparin. This became more noticeable in rats given the three drugs. The new study may offer a preventive method for drug-related osteoporosis that can be regarded as an enhanced and preventive treatment for the general populace, potentially reducing the expense of treating bone illnesses associated with osteoporosis.

ACKNOWLEDGMENTS: I'd like to thank study staff members and faculty from the pharmacy who helped with animal techniques. No. (871-22).

CONFLICT OF INTEREST: None

FINANCIAL SUPPORT: None

ETHICS STATEMENT: Ethical approval was cleared by the ethics committee of the Department of Biochemistry, College of Science, University of Jeddah, KSA (Reference No.871-22).

REFERENCES

- Downey PA, Siegel MI. Bone biology and the clinical implications for osteoporosis. *Phys Ther.* 2006;86(1):77-91. doi:10.1093/ptj/86.1.77
- Kini U, Nandeesh BN. Physiology of bone formation, remodeling, and metabolism. *Radionucl Hybrid Bone Imaging.* 2012:29-57.
- Nanci A. Ten cate's oral histology, development, structure and function. 8th ed. Reed Elsevier India Private Limited. 2008;92-121.
- Crockett JC, Mellis DJ, Scott DI, Helfrich MH. New knowledge on critical osteoclast formation and activation pathways from study of rare genetic diseases of osteoclasts: focus on the RANK/RANKL axis. *Osteoporos Int.* 2011;22(1):1-20. doi:10.1007/s00198-010-1272-8
- Boyce BF, Xing L. Functions of RANKL/RANK/OPG in bone modeling and remodeling. *Arch Biochem Biophys.* 2008;473(2):139-46. doi:10.1016/j.abb.2008.03.018
- Oduah EI, Linhardt RJ, Sharfstein ST. Heparin: Past, Present, and Future. *Pharmaceuticals (Basel).* 2016;9(3):38. doi:10.3390/ph9030038
- González-Castejón M, Visioli F, Rodriguez-Casado A. Diverse biological activities of dandelion. *Nutr Rev.* 2012;70(9):534-47. doi:10.1111/j.1753-4887.2012.00509.x
- Lazrak HH, René É, Elftouh N, Leblanc M, Lafrance JP. Safety of low-molecular-weight heparin compared to unfractionated heparin in hemodialysis: a systematic review and meta-analysis. *BMC Nephrol.* 2017;18(1):187. doi:10.1186/s12882-017-0596-4
- Quer PF, Davit S. Plantas medicinales: el dioscórides renovado (No. CIDAB-: RS164-F6p). Labor. 1993.
- Ata S, Farooq F, Javed S. Elemental profile of 24 common medicinal plants of Pakistan and its direct link with traditional uses. *J Med Plants Res.* 2011;5(26):6164-8.
- Abrams SA, Griffin IJ, Hawthorne KM, Liang L, Gunn SK, Darlington G, et al. A combination of prebiotic short- and long-chain inulin-type fructans enhances calcium absorption and bone mineralization in young adolescents. *Am J Clin Nutr.* 2005;82(2):471-6. doi:10.1093/ajcn.82.2.471
- Brzezińska O, Łukasik Z, Makowska J, Walczak K. Role of Vitamin C in Osteoporosis Development and Treatment-A Literature Review. *Nutrients.* 2020;12(8):2394. doi:10.3390/nu12082394
- Palacios C. The role of nutrients in bone health, from A to Z. *Crit Rev Food Sci Nutr.* 2006;46(8):621-8. doi:10.1080/10408390500466174
- Park JK, Lee EM, Kim AY, Lee EJ, Min CW, Kang KK, et al. Vitamin C deficiency accelerates bone loss inducing an increase in PPAR-γ expression in SMP30 knockout mice. *Int J Exp Pathol.* 2012;93(5):332-40. doi:10.1111/j.1365-2613.2012.00820.x
- Palermo A, Tuccinardi D, D'Onofrio L, Watanabe M, Maggi D, Maurizi AR, et al. Vitamin K and osteoporosis: Myth or reality? *Metabolism.* 2017;70:57-71. doi:10.1016/j.metabol.2017.01.032

16. Akbari S, Rasouli-Ghahroudi AA. Vitamin K and Bone Metabolism: A Review of the Latest Evidence in Preclinical Studies. *Biomed Res Int.* 2018;2018:4629383. doi:10.1155/2018/4629383
17. Fusaro M, Mereu MC, Aghi A, Iervasi G, Gallieni M. Vitamin K and bone. *Clin Cases Miner Bone Metab.* 2017;14(2):200-6. doi:10.11138/cmbm/2017.14.1.200
18. Muir JM, Andrew M, Hirsh J, Weitz JJ, Young E, Deschamps P, et al. Histomorphometric analysis of the effects of standard heparin on trabecular bone in vivo. *Blood.* 1996;88(4):1314-20.
19. Cho SY, Park JY, Park EM, Choi MS, Lee MK, Jeon SM, et al. Alteration of hepatic antioxidant enzyme activities and lipid profile in streptozotocin-induced diabetic rats by supplementation of dandelion water extract. *Clin Chim Acta.* 2002;317(1-2):109-17. doi:10.1016/s0009-8981(01)00762-8
20. Akiyama Y, Hara K, Kobayashi M, Tomiuga T, Nakamura T. Inhibitory effect of vitamin K2 (menatetrenone) on bone resorption in ovariectomized rats: a histomorphometric and dual energy X-ray absorptiometric study. *Jpn J Pharmacol.* 1999;80(1):67-74. doi:10.1254/jjp.80.67
21. Giordano V, Albuquerque RP, do Amaral NP, Chame CC, de Souza F, Apfel MÍ. Supplementary vitamin C does not accelerate bone healing in a rat tibia fracture model. *Acta Ortop Bras.* 2012;20(1):10-2. doi:10.1590/S1413-78522012000100001
22. Mussi Filho S, Canova RA, Cruz HAD, Vidigal L, Zaniolo FJ, Vialle LR G. The effects of low-molecular-weight heparin (Enoxaparin) on bony callus formation in rats' femurs-an experimental study. *Acta Ortopédica Brasileira.* 2006;14:78-82.
23. Simann M, Schneider V, Le Blanc S, Dotterweich J, Zehe V, Krug M, et al. Heparin affects human bone marrow stromal cell fate: Promoting osteogenic and reducing adipogenic differentiation and conversion. *Bone.* 2015;78:102-13. doi:10.1016/j.bone.2015.04.039
24. Yang S, Niu Q, Gan L, Zhang X, Tu L, Zuo L. Effect of long-term use of unfractionated or low-molecular-weight heparin on bone mineral density in maintenance hemodialysis patients. *Hemodial Int.* 2020;24(3):374-82. doi:10.1111/hdi.12854
25. Bick RL, Frenkel EP, Walenga J, Fareed J, Hoppensteadt DA. Unfractionated heparin, low molecular weight heparins, and pentasaccharide: basic mechanism of actions, pharmacology, and clinical use. *Hematol Oncol Clin North Am.* 2005;19(1):1-51. doi:10.1016/j.hoc.2004.09.003
26. Wayne C, Nguyen TH, Rollin J, Charuel N, Poupon A, Pouplard C, et al. Characterization of New Monoclonal PF4-Specific Antibodies as Useful Tools for Studies on Typical and Autoimmune Heparin-Induced Thrombocytopenia. *Thromb Haemost.* 2021;121(3):322-31. doi:10.1055/s-0040-1717078
27. Xue L, Jiao L, Wang Y, Nie Y, Han T, Jiang Y, et al. Effects and interaction of icariin, curculigoside, and berberine in er-xian decoction, a traditional chinese medicinal formula, on osteoclastic bone resorption. *Evid Based Complement Alternat Med.* 2012;2012:490843. doi:10.1155/2012/490843
28. Kwan Tat S, Padriens M, Théoleyre S, Heymann D, Fortun Y. IL-6, RANKL, TNF-alpha/IL-1: interrelations in bone resorption pathophysiology. *Cytokine Growth Factor Rev.* 2004;15(1):49-60. doi:10.1016/j.cytogfr.2003.10.005
29. DeLaurier A, Jackson B, Ingham K, Pfeiffer D, Horton MA, Price JS. Biochemical markers of bone turnover in the domestic cat: relationships with age and feline osteoclastic resorptive lesions. *J Nutr.* 2002;132(6 Suppl 2):1742S-4S. doi:10.1093/jn/132.6.1742S
30. Xia J, Zhang Z, Wang J, Zu J, Wang N, Wang D. Comparison of the effects of heparin and the direct factor Xa inhibitor, rivaroxaban, on bone microstructure and metabolism in adult rats. *Connect Tissue Res.* 2015;56(6):477-82. doi:10.3109/03008207.2015.1069285
31. Sakr HF, Hussein AM, Eid EA, Boudaka A, Lashin LS. Impact of Dehydroepiandrosterone (DHEA) on Bone Mineral Density and Bone Mineral Content in a Rat Model of Male Hypogonadism. *Vet Sci.* 2020;7(4):185. doi:10.3390/vetsci7040185
32. Halleen JM, Tiitinen SL, Ylipahkala H, Fagerlund KM, Väänänen HK. Tartrate-resistant acid phosphatase 5b (TRACP 5b) as a marker of bone resorption. *Clin Lab.* 2006;52(9-10):499-509.
33. Li B, Lu D, Chen Y, Zhao M, Zuo L. Unfractionated Heparin Promotes Osteoclast Formation in Vitro by Inhibiting Osteoprotegerin Activity. *Int J Mol Sci.* 2016;17(4):613. doi:10.3390/ijms17040613
34. Xiong J, Onal M, Jilka RL, Weinstein RS, Manolagas SC, O'Brien CA. Matrix-embedded cells control osteoclast formation. *Nat Med.* 2011;17(10):1235-41. doi:10.1038/nm.2448
35. Kuo TR, Chen CH. Bone biomarker for the clinical assessment of osteoporosis: recent developments and future perspectives. *Biomarker Res.* 2017;5(1):1-9.
36. Dai QG, Zhang P, Wu YQ, Ma XH, Pang J, Jiang LY, et al. Ovariectomy induces osteoporosis in the maxillary alveolar bone: an in vivo micro-CT and histomorphometric analysis in rats. *Oral Dis.* 2014;20(5):514-20. doi:10.1111/odi.12166
37. Wawrzyńska L, Tomkowski WZ, Przedlacki J, Hajduk B, Torbicki A. Changes in bone density during long-term administration of low-molecular-weight heparins or acenocoumarol for secondary prophylaxis of venous thromboembolism. *Pathophysiol Haemost Thromb.* 2003;33(2):64-7. doi:10.1159/000073848
38. Lee NK, Sowa H, Hinoi E, Ferron M, Ahn JD, Confavreux C, et al. Endocrine regulation of energy metabolism by the skeleton. *Cell.* 2007;130(3):456-69. doi:10.1016/j.cell.2007.05.047
39. Nishiyama M, Itoh F, Ujiiie A. Low-molecular-weight heparin (dalteparin) demonstrated a weaker effect on rat bone metabolism compared with heparin. *Jpn J Pharmacol.* 1997;74(1):59-68. doi:10.1254/jjp.74.59
40. Shaughnessy SG, Hirsh J, Bhandari M, Muir JM, Young E, Weitz JJ. A histomorphometric evaluation of heparin-induced bone loss after discontinuation of heparin treatment in rats. *Blood.* 1999;93(4):1231-6.
41. Aghajanian P, Hall S, Wongworawat MD, Mohan S. The Roles and Mechanisms of Actions of Vitamin C in Bone: New Developments. *J Bone Miner Res.* 2015;30(11):1945-55. doi:10.1002/jbmr.2709
42. Franceschi RT, Iyer BS. Relationship between collagen synthesis and expression of the osteoblast phenotype in MC3T3-E1 cells. *J Bone Miner Res.* 1992;7(2):235-46. doi:10.1002/jbmr.5650070216
43. Akman S, Canakci V, Kara A, Tozdoglu U, Arabaci T, Dagsuyu IM. Therapeutic effects of alpha lipoic acid and vitamin C on alveolar bone resorption after experimental periodontitis in rats: a biochemical, histochemical, and stereologic study. *J Periodontol.* 2013;84(5):666-74. doi:10.1902/jop.2012.120252
44. Villa JKD, Diaz MAN, Pizziolo VR, Martino HSD. Effect of vitamin K in bone metabolism and vascular calcification: A review of mechanisms of action and evidences. *Crit Rev Food Sci Nutr.* 2017;57(18):3959-70. doi:10.1080/10408398.2016.1211616
45. Kim M, Na W, Sohn C. Vitamin K1 (phyloquinone) and K2 (menaquinone-4) supplementation improves bone formation in a high-fat diet-induced obese mice. *J Clin Biochem Nutr.* 2013;53(2):108-13. doi:10.3164/jcbs.13-25
46. Poon CC, Li RW, Seto SW, Kong SK, Ho HP, Hoi MP, et al. In vitro vitamin K2 and 1α, 25-dihydroxyvitamin D3 combination enhances osteoblasts anabolism of diabetic mice. *Eur J Pharmacol.* 2015;767:30-40.
47. van Summeren M, Braam L, Noirt F, Kuis W, Vermeer C. Pronounced elevation of undercarboxylated osteocalcin in healthy children. *Pediatr Res.* 2007; 61(3):366-70. doi:10.1203/pdr.0b013e318030d0b1
48. Rangel LBA, de Siqueira D, do Rosário Soares O, Santana HS, de Castro Miguel E, da Cunha M, et al. Vitamin K supplementation modulates bone metabolism and ultra-structure of ovariectomized mice. *Cell Physiol Biochem.* 2018;51(1):356-74.