

# When Bad Luck Strikes Twice: Beckwith Wiedemann Syndrome Associated with Familial Long QT Syndrome Type I

Codruta Diana Petchesi<sup>1,2</sup>, Kinga Kozma<sup>1,3\*</sup>, Alin Remus Iuhas<sup>3,4</sup>, Ramona Hodisan<sup>1</sup>, Alexandru Daniel Jurca<sup>1</sup>

<sup>1</sup>Department of Preclinical Disciplines, Faculty of Medicine and Pharmacy, University of Oradea, Oradea, Romania. <sup>2</sup>Regional Center for Medical Genetics Bihor (part of ERN THACA), Bihor County Emergency Clinical Hospital, Oradea, Romania. <sup>3</sup>Bihor County Emergency Clinical Hospital, Oradea, Romania. <sup>4</sup>Department of Medical Disciplines, Faculty of Medicine and Pharmacy, University of Oradea, Oradea, Romania.

## Abstract

Long QT syndrome type I is an autosomal dominant condition caused by the heterozygotic loss of the *KCNQ1* gene function on the 11p15 chromosome. The *KCNQ1* gene is located on chromosome 11 in an area that has been the subject of genetic imprinting and is involved in another genetic condition, Beckwith-Wiedemann syndrome. The authors present the case of a girl with inherited type I long QT syndrome (the patient's mother and sister are affected) associated with Beckwith-Wiedemann syndrome by hypomethylation of the IC2 imprinting center. MS-MLPA showed hypomethylation of the KvDMR locus (IC2), and Sanger sequencing performed revealed a pathogenic mutational variant in the *KCNQ1* gene. Not every carrier of the pathogenic mutational variant in the *KCNQ1* gene and IC2 hypomethylation exhibits both genetic disorders, for reasons that are not fully explained. Early diagnosis, close multidisciplinary monitoring, and adequate treatment are critical to the patient's optimal development and good prognosis.

**Keywords:** Long QT type I, Beckwith-wiedemann, *KCNQ1*, IC2 hypomethylation

## INTRODUCTION

Long QT syndrome (LQTS) is an autosomal dominant condition that occurs in the general population with an incidence of 1 in 2,500 newborns [1]. There are 16 types of LQTS, LQTS type I or Ward-Romano syndrome, (MIM #192500) represents 38% of all LQTS. Around 10% of the patients have two mutational variants and present with a much more severe form. LQTS1 is caused by the heterozygotic loss of function of the KQT-like voltage-gated potassium channel-1 (*KCNQ1*) gene [2] on the 11p15 chromosome. Electrocardiographically it is characterized by an extended QT repolarization interval and polymorphic ventricular arrhythmias (torsade de pointes), which are more frequent in LQTS 1 and 2 than in the rest of the forms. Intense physical effort like swimming or strong emotions can generate ventricular tachycardia, syncope, or even sudden death. Although not all carriers of the mutation show clinical signs of the disease, it is an important cause of sudden death, especially in young people. The medical management of the case relies on medical treatment with beta-blockers and lifestyle measures [3].

Beckwith-Wiedemann syndrome (MIM #130650) is an overgrowth syndrome with a prevalence at birth of 1 in 12,000 newborns [4]. It is characterized by macrosomia, macroglossia, and postnatal hypoglycemia, as well as an increased risk of developing embryonic tumors such as

Wilms tumor, hepatoblastoma, neuroblastoma, adrenal carcinoma, or rhabdomyosarcoma [5-7]. The clinical diagnosis is based on the new BWS consensus scoring system (**Table 1**) [8-10], cardinal features are awarded 2 points each, and suggestive features are awarded 1 point each. A total of 4 points is sufficient for a clinical diagnosis and a total of 2 points suggests the need for molecular testing.

**Address for correspondence:** Kinga Kozma, Department of Preclinical Disciplines, Faculty of Medicine and Pharmacy, University of Oradea, Oradea, Romania.  
kozma.k@gmail.com

This is an open-access article distributed under the terms of the Creative Commons Attribution-Non Commercial-Share Alike 4.0 License, which allows others to remix, tweak, and build upon the work non commercially, as long as the author is credited and the new creations are licensed under the identical terms.

**How to cite this article:** Petchesi CD, Kozma K, Iuhas AR, Hodisan R, Jurca AD. When Bad Luck Strikes Twice: Beckwith Wiedemann Syndrome Associated with Familial Long QT Syndrome Type I. Arch Pharm Pract. 2024;15(3):49-53.  
<https://doi.org/10.51847/Co1unfeMPY>

**Table 1.** BWS consensus scoring system

Cardinal features	Suggestive features
Macroglossia	Birth weight >2 standard deviation scores (SDS) above mean
Hyperinsulinism	Facial nevus simplex
	Omphalocele
	Polyhydramnios and/or placentomegaly
Lateralized overgrowth/hemihypertrophy	Ear creases and/or pits
Multifocal Wilms tumor/nephroblastomatosis	Transient hypoglycemia
Pathology findings including adrenal cortical cytomegaly, placental mesenchymal dysplasia, or pancreatic adenomatosis	Embryonal tumors (hepatoblastoma, isolated Wilms tumor, neuroblastoma, pheochromocytoma, rhabdomyosarcoma, adrenocortical carcinoma)
	Nephromegaly and or hepatomegaly
	Umbilical hernia/diastasis recti

It is genetically heterogeneous, being caused by various abnormalities of the growth-regulating genes located on the 11p15 chromosome. This region is subject to genetic imprinting and contains two independently regulated clusters [11]: IC1 (Imprinting center 1), methylated on the paternal allele, and IC2 (Imprinting center 2), methylated on the maternal allele. Most patients have methylation defects of one or both centers [12] paternal uniparental disomy occurs in 20% of cases, approximately 10-15% of cases without molecular confirmation, although the clinical picture is clearly outlined. All diagnosed patients should have tumor screening, by full abdominal ultrasound and alpha-fetoprotein dosage every 3 months until the age of 4 years, and renal ultrasound every 3 months between the age of 4 and 7 years [13].

## MATERIALS AND METHODS

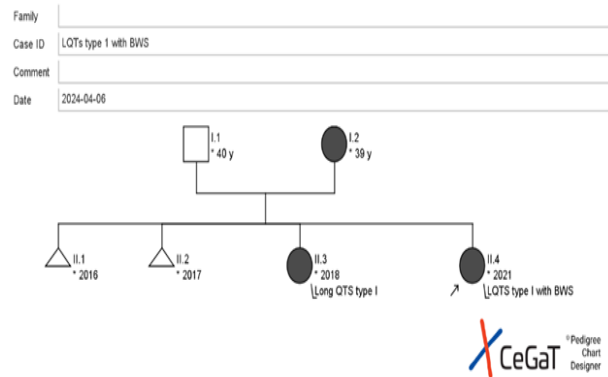
The authors describe a case of a girl with a rare association between Beckwith-Wiedemann syndrome and familial LQTS type I, monitored by the Regional Center for Medical Genetics Bihor since 2022. The clinical diagnosis of Beckwith-Wiedemann syndrome was molecularly confirmed at Bambino Gesù Roma Pediatric Hospital through MS-MLPA which highlights IC2 locus hypomethylation, associated with BWS. The molecular diagnosis performed in the same hospital showed a pathogenic mutation in the gene *KCNQ1*, inherited from the mother: NM\_000218.3 *KCNQ1*:c.604G>A, p.Asp202Asn.

## RESULTS AND DISCUSSION

Our case is a girl, the second child in the family (**Figure 1**). She was born at 37 gestational weeks, from an IVF (in vitro

fertilization) pregnancy, with last trimester preeclampsia. The birth weight and length were over percentile 90 (4220 gr, 53 cm), and she presented hemangiomas. Paraclinical, highly increased values of alpha-fetoprotein (AFP) and marked neonatal hypoglycemia were detected.

*Family history* reveals a positive history for LQTS1, both the mother and the older sister have genetically confirmed LQTS1. The father of our patient had a spontaneously closed atrial septum defect (ASD).



**Figure 1.** Family tree - index case II.4

*Cardiological examination* and Holter electrocardiogram (EKG) showed sinus rhythm, a heart rate of 145 bpm, and QT intervals above the normal limit. There were no noticeable arrhythmias or pathological breaks found. Echocardiography revealed a 3 mm atrial septum defect (ostium secundum type), with a left-right shunt.

Abdominal ultrasound showed hepatomegaly and a bifid bassinet of the right kidney, without expansion of the excretory pathways.

## Molecular Diagnosis

Methylation-specific Multiplex Ligation-dependent Probe Amplification (MS-MLPA) analysis was performed with a commercially available kit specific for the diagnosis of Beckwith Wiedemann/Silver-Russell syndromes (SALSA MS-MLPA ME030-B2 BWS/RSS). The analysis showed hypomethylation of the KvDMR locus (IC2), which confirmed the clinical diagnosis. Sanger sequencing performed showed a pathogenic mutational variant in the *KCNQ1* gene (class 5 AMG), the same variant present in the other two affected members of the family: NM\_000218.3 *KCNQ1*: c.604G>A, p.Asp202Asn. Both analyses were performed at Bambino Gesù Hospital in Rome.

## Case Management

The case has been registered with the Regional Center for Medical Genetics Bihor since the child was 13 months old. She is currently two years and five months old and has been followed up by our team on clinical, paraclinical, and imaging parameters to date. Regarding LQTS1, currently

follows medical treatment with beta-blocker medication (Nadolol) with periodic adjustment of the dose, under the supervision of the pediatric cardiology specialists. Health education is very important, there are commonly used medicines like antibiotics that can decompensate the disorder; the family has been informed on the medicines to be avoided [14]. Also, a list of potassium-rich foods was provided to follow, especially in summer or in case of dehydration.

Clinical, paraclinical, and imaging evaluation is performed every 3 months, as recommended by international guides and it follows the clinical examination, the dosage of alpha-fetoprotein, and abdominopelvic ultrasound [15, 16].

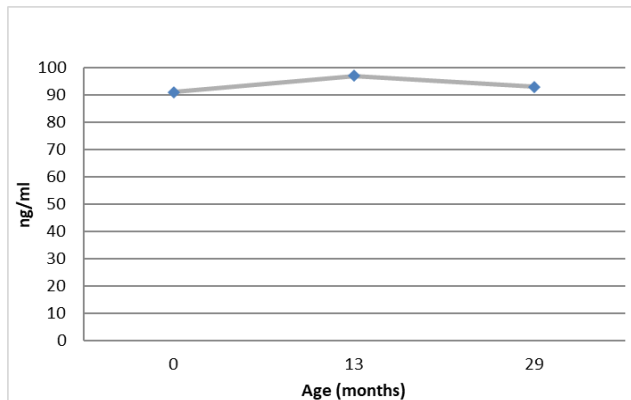
In evolution, the clinical and paraclinical parameters have been improved (**Table 2**).

**Table 2.** The evolution of clinical and paraclinical parameters

		At birth	13 months	2 years 5 months
<b>Alpha fetoprotein</b>	(NV < 7ng/ml)	92 ng/ml	24,61 ng/ml	12,79 ng/ml
<b>Weight</b>		4220 gr (> percentile 90)	15,6 kg (> percentile 97)	16,5 kg (percentile 90-95)

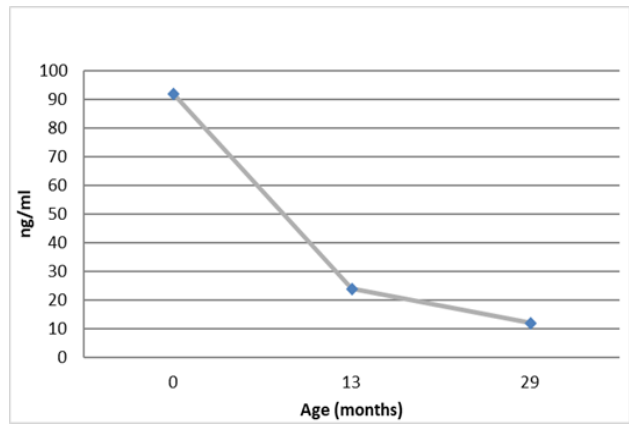
Note NV= normal value

There was an important improvement in the weight of the patient in time. When the patient registered with our center (13 months old) it was high above the percentile 97, and it is now between percentiles 90 and 95 (**Table 1, Figure 2**).



**Figure 2.** Evolution of weight

Alpha-fetoprotein has decreased from 92 ng/ml at birth to 12,79 ng/ml at present (**Table 1, Figure 3**). It is still above the normal values (below 7 ng/ml), but the descending trend of the parameter suggests a good outcome.



**Figure 3.** Evolution of Alpha-fetoprotein

The ultrasound did not reveal any changes over time. The patient will continue prophylactic abdominal ultrasound monitoring until the age of 4 years, and after that will continue with renal ultrasound until she reaches the age of 7 years old.

As a side effect of beta-blocker medication, quick and complete resorption of the hemangiomas has been noticed.

The patient presents a rare association of two rare genetic syndromes, rarely described in the literature. As far as we know this is the first case described in Romania.

Autosomal genes are expressed biallelically while imprinted genes are expressed either from the maternal or from the paternal allele. Imprinted genes are regulated by specific imprinting regions, located near the gene, which contain epigenetic marks that coordinate the expression of the gene (methylation of the gene). The location for the KCNQ1 gene is in a region of chromosome 11 subjected to genetic imprinting. Our patient has hypomethylation of Imprinting Center 2 on the maternal allele, where the KCNQ1 gene is located [17]. The gene contains 16 exons and spans 400 kb [18] and codes for a protein with structural features of a voltage-gated potassium channel. KCNQ1 is expressed only from the maternal allele except in the heart where both copies of the gene are expressed [19]. An antisense coding region, designated KCNQ10T1, exclusively expressed from the paternal allele, is located within the KCNQ1 locus, between exons 10 and 11.

Not every carrier of the pathogen mutational variant in the KCNQ1 gene and IC2 hypomethylation exhibits both genetic disorders, for reasons that are not fully explained. The exact role of the KCNQ1 gene in the etiology of BWS is not yet understood. In our case, the mother of the patient was first diagnosed with LQTS1 at the birth of the first child. She did not have any signs until preeclampsia in the last semester of the pregnancy and never showed any features of BWS.

The first case of the association of BWS and LQTS1 was found in a family where three BWS-affected offspring of a

carrier mother were identified as having BWS because of downregulation of the maternal copy of CDKN1C as a result of ICR2 deletion [20]. A second family also reported a comparable ICR2 deletion, where maternal transmission resulted in an offspring with a BWS phenotype due to CDKN1C underexpression [21]. A recent case of BWS and severe LQTS1 was described by Gurrieri *et al.* [22]. The patient, a 20-year-old woman, had a cardiac arrest related to LQTS1 and a mild phenotype of BWS. The underlying defect was a microdeletion of the IC2 region, a deletion that included the maternal copy of *KCNQ10T1*, and part of the *KCNQ1* maternal allele. The paternal *KCNQ1* allele is normally inactive and the maternal allele was inactivated by the deletion. First-degree relative screening allowed the diagnosis of mild LQTS1 in the patient's mother. In another case of a maternally inherited ICR2 deletion that included CDKN1C, as well as additional genes, the BWS phenotype is explained as due to the lack of the maternal CDKN1C transcript [23].

In 1993 Bonduelle suggested that death in utero is an expression of the Ward-Romano syndrome in some families [1]. Regarding the first two miscarried pregnancies of the family, as no preimplantation diagnosis was made, we cannot exclude this possibility. We are suggesting that in cases of LQTS due to mutation of the *KCNQ1* gene (LQTS1), an accurate clinical genetic evaluation should be done to program the most appropriate genetic tests for the affected patients and after that for the extended family. Extended genotype-phenotype correlation studies are necessary for a better understanding of the presented association of syndromes.

### Genetic Counselling

The recurrence risk for LQTS type I is 50% for each subsequent pregnancy of the couple and the proband's offspring. The risk of BWS cannot be specified, as not all the carriers of the hypomethylation of IC2 will exhibit signs of BWS.

### CONCLUSION

Only a few reported cases are describing this rare association of syndromes. The exact processes underlying the syndrome association in certain patients require further investigation. Early diagnosis is critical to the patient's development and prognosis and periodic monitoring. The multidisciplinary team makes a significant contribution.

**ACKNOWLEDGMENTS:** None

**CONFLICT OF INTEREST:** None

**FINANCIAL SUPPORT:** None

**ETHICS STATEMENT:** The study was conducted according to the guidelines of the Declaration of Helsinki and was approved by the Ethics Committee of Bihor County Emergency Clinical Hospital, Oradea, Romania Nr. 11327/05.04.2024. Written informed consent was obtained from the mother of the patient enrolled in the study.

### REFERENCES

1. Online Mendelian Inheritance in Man. Long QT syndrome type 1. 2021 [updated 2021 August 23; cited 2024 Apr 25]. Available from: <https://www.omim.org/entry/192500/>
2. Melgar Quicaño LA, Chipa Ccasani F. Congenital long QT syndrome. Arch Peru Cardiol Cir Cardiovasc. 2021;2(1):49-57. doi:10.47487/apcyccv.v2i1.125
3. Wilde AA, Amin AS, Postema PG. Diagnosis, management and therapeutic strategies for congenital long QT syndrome. Heart. 2022;108(5):332-8.
4. Online Mendelian Inheritance in Man. Beckwith-Wiedemann syndrome. 2023 [updated 2023 Jan 19; cited 2024 Apr 25]. Available from: <https://www.omim.org/entry/130650>
5. Jurcă MC, Ivaşcu ME, Jurcă AA, Kozma K, Magyar I, Şandor MI, et al. Genetics of congenital solid tumors. Rom J Morphol Embryol. 2020;61(4):1039-49. doi:10.47162/RJME.61.4.06
6. Cancer. Net. Beckwith-Wiedemann syndrome. 2024 [updated March 2024; cited 2024 Apr 25]. Available from: <https://www.cancer.net/cancer-types/beckwith-wiedemann-syndrome>
7. Brioude F, Kalish JM, Mussa A, Foster AC, Blied J, Ferrero GB, et al. Expert consensus document: Clinical and molecular diagnosis, screening and management of Beckwith-Wiedemann syndrome: An international consensus statement. Nat Rev Endocrinol. 2018;14(4):229-49. doi:10.1038/nrendo.2017.166
8. Library of Medicine. Beckwith-Wiedemann syndrome. 2024 [updated 7 Jan 2024; cited 2024 Apr 25]. Available from: <https://www.ncbi.nlm.nih.gov/books/NBK558993/>
9. Elbracht M, Prawitt D, Nemetschek R, Kratz C, Eggermann T. Beckwith-Wiedemann-syndrom (BWS): Aktueller stand der diagnostik und des klinischen managements. Klin Padiatr. 2018;230(03):151-9. doi:10.1055/a-0591-9479
10. Wang KH, Kupa J, Duffy KA, Kalish JM. Diagnosis and management of Beckwith-Wiedemann syndrome. Front Pediatr. 2020;7:562. doi:10.3389/fped.2019.00562
11. Maas SM, Vansenne F, Kadouch DJ, Ibrahim A, Blied J, Hopman S, et al. Phenotype, cancer risk, and surveillance in Beckwith-Wiedemann syndrome depending on molecular genetic subgroups. Am J Med Genet A. 2016;170(9):2248-60. doi:10.1002/ajmg.a.37801
12. Medscape. Beckwith-Wiedemann syndrome. 2023 [updated 2023 April 18; cited 2024 Apr 25]. Available from <https://emedicine.medscape.com/article/919477-overview>.
13. Kalish JM, Doros L, Helman LJ, Hennekam RC, Kuiper RP, Maas SM, et al. Surveillance recommendations for children with overgrowth syndromes and predisposition to Wilms tumors and Hepatoblastoma. Clin Cancer Res. 2017;23(13):e115-22.
14. Fazio G, Vernuccio F, Grutta G, Re GL. Drugs to be avoided in patients with long QT syndrome: Focus on the anaesthesiological management. World J Cardiol. 2013;5(4):87-93. doi:10.4330/wjc.v5.i4.87
15. Eggermann T, Brück J, Knopp C, Fekete G, Kratz C, Tasic V, et al. Need for a precise molecular diagnosis in Beckwith-Wiedemann and Silver-Russell syndrome: What has to be considered and why it is important. J Mol Med (Berl). 2020;98(10):1447-55. doi:10.1007/s00109-020-01966-z
16. Al-Khatib SM, Stevenson WG, Ackerman MJ, Bryant WJ, Callans DJ, Curtis AB, et al. 2017 AHA/ACC/HRS guideline for management of patients with ventricular arrhythmias and the prevention of sudden cardiac death: A report of the American college of cardiology/American heart association task force on clinical practice guidelines and the heart rhythm society. Circulation. 2018;138(13):e272-391. doi:10.1161/CIR.0000000000000549
17. Medline Plus. *KCNQ1* gene. 2017 [updated 2017 Sept 1; cited 2024 Apr 25]. Available from: <https://medlineplus.gov/genetics/gene/kcnq1/>
18. Lu H, Ding W, Xiao H, Dai M, Xue Y, Jia Z, et al. Association of the P441L *KCNQ1* variant with severity of long QT syndrome and risk of cardiac events. Front Cardiovasc Med. 2022;9:922335. doi:10.3389/fcvm.2022.922335
19. Amigo Gene Ontology. *KCNQ1* gene. 2024 [updated 2024 April 19; cited 2024 Apr 25]. Available from [https://amigo.geneontology.org/amigo/gene\\_product/UniProtKB:P51787](https://amigo.geneontology.org/amigo/gene_product/UniProtKB:P51787)

20. Niemitz EL, DeBaun MR, Fallon J, Murakami K, Kugoh H, Oshimura M, et al. Microdeletion of LIT1 in familial Beckwith-Wiedemann syndrome. *Am J Hum Genet.* 2004;75(5):844-9.
21. Algar E, Dagar V, Sebah M, Pachter N. An 11p15 imprinting centre region 2 deletion in a family with Beckwith Wiedemann syndrome provides insights into imprinting control at CDKN1C. *PLoS One.* 2011;6(12):e29034.
22. Gurrieri F, Zollino M, Oliva A, Pascali V, Orteschi D, Pietrobono R, et al. Mild Beckwith-Wiedemann and severe long-QT syndrome due to deletion of the imprinting center 2 on chromosome 11p. *Eur J Hum Genet.* 2013;21(9):965-9. doi:10.1038/ejhg.2012.280
23. Zollino M, Orteschi D, Marangi G, De Crescenzo A, Pecile V, Riccio A, et al. A case of Beckwith-Wiedemann syndrome caused by a cryptic 11p15 deletion encompassing the centromeric imprinted domain of the BWS locus. *J Med Genet.* 2010;47(6):429-32.