Original Article

Value of Tip-Apex Distance (TAD) in the Fixation of Intertrochanteric Fractures by Dynamic Hip Screw (DHS)

Hossam Mohamed Khairy, Ali Tawfik El-Alfy, Ahmed Elsayed El-Malt, Ramy Nabil Samy*

Department of Orthopedic Surgery, Faculty of Medicine – Zagazig University, Egypt.

Abstract

Background: The fixation of ITF by DHS allows the compression of the fracture when the patients bear weight. Placement of lag screw should be central in the head and neck of the femur. This study aimed to emphasize the clinical value of the tip apex distance as a reliable predictor of the cut-out of the lag screw in the fixation of stable ITF. **Patients & Methods:** This was a retrospective cohort study that included 18 cases, skeletally mature patients with post-traumatic intertrochanteric fractures treated with DHS in the period from January 2016 to December 2016 with follow up of at least six months at Zagazig University Hospital. ITFs were internally fixated with DHS, and by postoperative follow-up, we measured the TAD post-operatively and after 6 months to detect the importance of TAD on the stability of lag screw in the head and neck of the femur and reported cases that developed cut-through of the lag screw. **Results:** TAD was the main measurement in the study. The rate of implant failure and cut-through was 27.8%. The median of TAD postoperative was 2.05. The median of TAD after 6 months was 2.23. There was a highly significant difference between the median of TAD after 6 months that developed cut-through and median of TAD after 6 months that did not develop cut-through (p-value <0.001). **Conclusions:** TAD of less than 25mm is safe and more than 25mm may result in the penetration of implant, non-union, cut-through, and other complications. Therefore, TAD is a reliable factor and has great value in DHS operations.

Keywords: Value of Tip-Apex Distance (TAD), intertrochanteric fractures (ITF), cut-through, dynamic hip screw (DHS)

Introduction

The neck of femur fracture is a prevalent problem mostly observed among the people who have extra-capsular fractures such as pertrochanteric and intertrochanteric fractures also known as peritrochanteric fractures, and are commonly treated with compression hip screw (CHS) or dynamic hip screw (DHS) [1].

The DHS is on the basis of the tension band principle and allows the screw to slide in the barrel in order to enable the fracture compression when the patient starts to bear weight. This principle works only in the presence of the intact medial wall and therefore cannot be successful in a reverse oblique fracture of the proximal femur [2].

Nevertheless, it is crucial that the screw placement technique is accurate and should be central in the femoral neck, on both lateral and AP radiographs. That is why the Tip Apex Distance (TAD) concept has a great impact on the result of fixation and can exactly predict the survival or failure of the screw [3].

The concept of TAD came up in 1995, and then in 1997 by Baumgaertner et al., as they acknowledged the importance of an appropriate surgical technique in the treatment of trochanteric fractures using TAD as a useful clinical method to describe the screw position [4].

TAD is the distance from the screw tip to the apex of the femoral head on AP and lateral views. TAD should be below 25mm in order to prevent DHS cut-out or failure, which most often happens if the screw is placed too superior or too anterior [5].

Aim of the Work

Address for correspondence: Ramy Nabil Samy. Resident doctor in the Department of Orthopedic Surgery.
E-mail: ramy.beskales.ortho @ gmail.com

How to cite this article: Khairy, H.M., El-Alfy, A.T., El-Malt,A.E., R Samy,R.M., Value of Tip-Apex Distance (TAD) in the Fixation of Intertrochanteric Fractures by Dynamic Hip Screw (DHS). Arch Pharma Pract 2019;10(3):81-6.

This study emphasized the clinical value of TAD as a reliable predictor of the lag screw cut-out used for the fixation of a stable intertrochanteric fracture of the hip.

Patients and Methods

This is a retrospective cohort study including 18 cases who were skeletally mature patients with post-traumatic intertrochanteric fractures treated with DHS in the period from January 2016 to December 2016 with a follow up of at least 6 months in the Zagazig University Hospital. The ITFs were internally fixated with DHS and postoperative follow-up. We measured the TAD postoperatively and after 6 months to detect the importance of TAD in the stability of lag screw in the head and neck of femur and reported cases that developed cut-through the lag screw.

Ethical

The study was approved by the Orthopedic Surgery Department, Zagazig University Hospital after taking Institutional Review Board (IRB) approval. This study was done in accordance with the ethics code of the World Medical Association (Declaration of Helsinki) for studies involving humans.

Inclusion criteria: Patients with an isolated intertrochanteric femur fracture. Fracture fixation was done by DHS. Follow up for at least 6 months.

Exclusion criteria: Pathological fracture. Pre-existing femoral acetabular deformities such as coxa vara, acetabulum dysplasia or previous malunion. Intertrochanteric Femoral fracture with associated posteromedial comminution and reverse obliquity.

All patients were subjected to complete radiological and clinical evaluations: X-ray was done in anteroposterior, lateral views, and anteroposterior pelvis with traction and internal rotation of the lower limb. Besides the routine preoperative investigations that were carried out for all patients, further special investigations were requested by the anesthesiologist to complete anesthetic judgment. Two units of blood were prepared for each patient, but their use was according to the individual situation.

All patients received a single dose of third-generation cephalosporin as antibiotic prophylaxis; 1000mg was given 30 minutes before incision as prophylaxis, every 12 hours and continued for 3 days postoperatively.

Surgical Technique:

Patients were placed in the supine position and the traction table was used in all patients. Under image intensification guidance, closed reduction was done using traction and slight abduction and internal rotation. The reduction quality was evaluated as explained by Baumgaertner et al.

The reduction was satisfactory when there was smooth anterior and medial cortical bony buttressing. The lateral approach of the proximal femur was used in all patients. Fixation was done by DHS and the plate. Lag screws lengths, in the study, were from 80 mm to 105 mm. 4 – 6 hole plates were used. Anti-medialisation plate and Anti-rotational screws were not used. Bone graft and cement were not used in this study.

Closure of the wound (muscle layer vastus lateralis and an iliotibial tract by continuously locked sutures and subcutaneous layer then skin by mattress sutures and simple sutures).

Method of the measurement of TAD

- A line drawing showing the measurement of the TAD.
- Use of the true diameter of the screw (D true) controlled for magnification.
- (D true) is the known diameter of the lag screw. (D lat) is the lag screw diameter on a lateral radiograph. (D ap) is the lag screw diameter on an anteroposterior radiograph. (X ap) is the distance from the screw tip to the center of the femoral head on an anteroposterior radiograph. (X lat) is the distance from the screw tip to the center of the femoral head on a lateral radiograph.
- TAD is measured by the summation of the distance in mm from the lag screw tip to the apex of the femoral head as measured on an anteroposterior radiograph and that distance as measured on a lateral radiograph after correction is made for magnification.
- The Apex of the femoral head is the intersection point between the subchondral bone and a line in the parallel to and center of the femoral neck.
- The amount of radiographic magnification is determined by dividing the diameter of the projected shaft of the screw as observed on the radiograph by its known diameter and correction is achieved by multiplying the measurement of the distance by this factor. The radiographs assess union, nonunion, and screw cut out as endpoints (Figure 1).

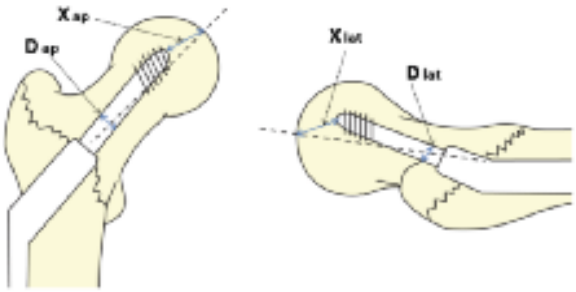

$$TAD = \left(X_{ap} \times \frac{D_{true}}{D_{ap}}\right) + \left(X_{lat} \times \frac{D_{true}}{D_{lat}}\right)$$

Postoperative Management:

In the recovery room, the patients' pulse and blood pressure were checked. Three patients needed to enter the ICU postoperatively and discharged on the second day. 15 patients were admitted to the entire department without ICU need.

Follow up:

DVT prophylaxis was done using oral anticoagulants. The first follow up out the clinic was done two weeks after surgery to remove the sutures. Protected weight bearing using crutches was advised for 6-8 weeks or until full union detected by x-ray. Data was clinically and radiologically collected by immediate postoperative imaging and outpatient clinic follow up after 2 and 6 months; clinically by range of motion, tenderness, and Ober's test; and radiologically anteroposterior and lateral radiographs, TAD, union callus, bone bridge, malunion, varus deformity, shortening measured by tape, the complication of metal as osteolysis, metal failure, cut-through, and infection.

Case: Male patient, 59 years old, fall on the ground.

X-ray: Intertrochanteric fracture in the left femur. ORIF was done by DHS. Acceptable quality of reduction. The TAD measurement postoperative was 2.88 cm. TAD measurement after 6 months was 3.7 cm.

Postoperatively: Cut-through of the lag screw from the femoral head and defective union.

Pre-operative:

Figure 1: Preoperative x-ray showed non-displaced ITF in left femur.

Post-operative:

Figure 2: Postoperative study revealed an acceptable quality of reduction. TAD was 2.88 cm.

After 6 months:

Figure 3: After 6 months, there was a defective union with partial weight-bearing on crutches suffering from pain on the left hip and limb. TAD was 3.7 cm. There was the cut-through of the lag screw from the femoral head.

Results:

Table 1: Relationship between degrees of the quality of reduction and cut-through

Quality of reduction	Cut-Through				P-value
	Yes		No		
	No.	%	No.	%	
Good	0	0.0	9	69.2	
Acceptable	4	80.0	3	23.1	**0.031***
Poor	1	20.0	1	7.7	

The quality of reduction was statistically significant in the presence of cut-through (p-value = 0.031). All cases that had a good quality of reduction did not develop a cut-through, an acceptable type of reduction was (80%) developed cut-through but 23.1% did not have cut-through, 20% developed cut-through and 7.7% did not develop cut-through **(Table 1)**.

Table 2: Comparison of TAD between postoperative and after 6 months according to the cut-through

Cut-Through	Yes	No	P-value
	Median (IQ)	Median (IQ)	
TAD - postoperative	2.89(2.57-3.04)	1.8(1.71-2.22)	<0.001**
TAD - 6 months	3.59(2.7-4.11)	2.17(1.96-2.27)	<0.001**

Mann-whitney U,
* Statistically significant difference (p <0.05),
** Highly statistically significant difference (p <0.01).

The median of postoperative TAD measurement that developed cut-through was [2.89 (2.57-3.04)], and the median of postoperative TAD measurement that did not develop cut-through was [1.8 (1.71-2.22)]. The median of TAD measurement after 6 months that developed cut-through was [3.59 (2.7-4.11)], and the median of TAD measurement after 6 months that did not develop cut-through was [2.17 (1.96-2.27)]. **Table 2**

Table 3: Comparison between TAD in postoperative and after 6 months with significance

	Median (IQ)	P-value
TAD - postoperative	2.05(1.72-2.74)	**0.020***
TAD – 6 months	2.23(1.98-2.70)	

Wilcoxon test
* Statistically significant difference (p <0.05)
****** Highly statistically significant difference (p <0.01).

TAD was the main measurement in the study that could detect the outcome of DHS fixation especially for the cut-through of the lag screw. The median of TAD postoperative was [2.05 (1.72-2.74)]. The median of TAD after 6 months was [2.23 (1.98-2.70)]. There was a significant difference between TAD postoperative and TAD after 6 months (p-value=0.020). There was a highly significant difference between the median of TAD postoperative that developed cut-through of the lag screw and the TAD postoperative that did not develop cut-through (p-value <0.001) **(Table 3)**.

Discussion:

Proximal femoral fractures are common in the elderly age and result in a heavy burden to the affected individuals and society. Its frequency is increasing with the more aging population. Early operative treatment decreases morbidity and mortality, reducing the risk of prolonged bed rest and giving the best chance of early independence [6].

Internal fixation enables early mobilization. Sliding hip screws are widely used but are associated with problems. The ideal implant should enable full weight-bearing immediately after surgery, be easy to handle, and provide enough purchase in the femoral head/neck fragment to limit cut-outs secondary to varus rotation and deviation [7].

For unstable trochanteric fractures treated with extramedullary devices such as the DHS, there were high varus-displacement and cut-out rates, wound problems, and infections. The extramedullary devices seem to be better than intramedullary ones when the fractures are stable [8].

The importance of the screw position in the femoral head has been recognized in the anteroposterior radiograph and posterior in the lateral radiograph aiming for better bone stock in the femoral head; however, by inferiorly and posteriorly positioning of the screw, the screw tip ended in more cancellous bone and not in the preferred subchondral bone, which leads to the failure of the implant [9].

Quality of reduction was classified into 3 groups as Baumgaertner, et al. noted that reduction was assessed on the amount of displacement and neck-shaft alignment on immediate postoperative AP and lateral radiographs, being categorized as poor, acceptable, or good [10].

Agni et al. showed that there are predictive factors for lag screw cut-out, the most important determining factor is the TAD, in addition to other factors including the degree of comminution of the fracture site and quality of reduction. That was demonstrated by our study [11].

Baumgaertner et al. demonstrated the TAD as a reproducible useful tool to evaluate the adequacy of sliding hip screw fixation. Describing the TAD calculation to evaluate the adequacy of the placement of lag screw in the femoral head, and regression defined the TAD >25mm as unsafe due to the increased risk of associated lag screw cut-out [10].

But, in our study, we found that TAD of 4 cases was above 25 mm postoperatively and developed cut-through of lag screw from the femoral head after 6 months by radiologically follow up; 1 case had a TAD above 25 mm but did not develop cut-through, which would be explained by good bone quality intact lateral wall, no technical errors, young age, thin body, and delayed weight-bearing. These factors also detected the presence of cut-through besides the measurement of TAD. The study included 13 cases with TAD below 25 mm, 12 cases of which did not develop cut-through, and 1 case of which developed cut-through. These results are in line with the study conducted by Hsueh et al [3].

Therefore, Davies, et al. noticed that there are other factors that judge the presence of cut-through including infection, posteromedial comminution, osteolysis, quality of reduction severe osteoporosis, and the quality of bone for purchase within the head and neck varies from one quadrant to another. The optimal position of a compression screw should be central or slightly central inferior. The bone of the lowest quality is in the anterosuperior aspect of the head and neck [5].

The incidence of screw cut-out ranges from 2.0% as reported by Chua et al. [12] to as high as 12.6%.

In the present study, we found another result that the incidence of screw cut-out was 27.8%. The mean time to screw cut-out was 3.8 months (ranged from 1 to 6 months) postoperatively, which is similar to the findings of Geller JA as well.

Conclusion:

TAD of less 25mm is safe and more than 25mm may result in the penetration of implant, non-union, cut-through, and other complications. Therefore, TAD is a reliable factor and has great value in DHS operations.

Recommendation:

We recommend that this TAD principle to be emphasized and regularly reinforced to all orthopedic trainees in order to improve the outcome of intertrochanteric fractures of the hip that are fixed by DHS, and so improve the safety and quality of life for the patients.

References

1. LEE JK, KHIR AS. The incidence of hip fracture in Malaysians above 50 years of age: variation in different ethnic groups. APLAR Journal of Rheumatology. 2007 Dec;10(4):300-5.
2. Clement ND, Green K, Murray N, Duckworth AD, McQueen MM. Undisplaced intracapsular hip fractures in the elderly: predicting fixation failure and mortality. A prospective study of 162 patients. Journal of Orthopaedic Science. 2013 Jul 1;18(4):578-85.
3. Hsueh KK, Fang CK, Chen CM, Su YP, Wu HF, Chiu FY. Risk factors in cutout of sliding hip screw in intertrochanteric fractures: an evaluation of 937 patients. International orthopaedics. 2010 Dec 1;34(8):1273-6.
4. Güven M, Yavuz U, Kadıoğlu B, Akman B, Kılınçoğlu V, Ünay K, Altıntaş F. Importance of screw position in intertrochanteric femoral fractures treated by dynamic hip screw. Orthopaedics & Traumatology: Surgery & Research. 2010 Feb 1;96(1):21-7.
5. Davies J, Mokawem M, Guy S. Tip Apex Distance: a useful method to assess extra-capsular neck of femur fixation. J Trauma Treatment. 2012;1(119):2167-1222.
6. Sharma G, Singh R, Gn KK, Jain V, Gupta A, Gamanagatti S, Farooque K, Sharma V. Which AO/OTA 31-A2 pertrochanteric fractures can be treated with a dynamic hip screw without developing a lateral wall fracture? A CT-based study. International orthopaedics. 2016 May 1;40(5):1009-17.
7. Bajpai J, Maheshwari R, Bajpai A, Saini S. Treatment options for unstable trochanteric fractures: Screw or helical proximal femoral nail. Chinese Journal of Traumatology. 2015 Dec 1;18(6):342-6.
8. Müller MC, Belei P, Strake M, Weber O, Burger C, Radermacher K, Wirtz DC. Evaluation of a 2d fluoroscopy-based navigation system for insertion of the dynamic hip screw (dhs): An experimental study. RoFo: Fortschritte auf dem Gebiete der Rontgenstrahlen und der Nuklearmedizin. 2011 Jun;183(6):536-42.
9. AL-Obidi FA. Tip Apex Distance as a Predicting Factor for the Outcome of Femoral Intertrochanteric Fracture Fixed by Dynamic Hip Screw. Iraqi Academic Scientific Journal. 2013;12(4):541-5.
10. Baumgaertner M, Curtin S, Lindskog D, Keggi JM. The value of the tip-apex distance in predicting failure of fixation of. J Bone Joint Surg Am. 1995;77:1058-64.
11. 1Agni N, Sellers EL, Johnson R, Gray AC. Tip Apex Distance–Is It Enough To Predict Implant Failure?. InOrthopaedic Proceedings 2012 Jul (Vol. 94, No. SUPP_XXXII, pp. 7-7). The British Editorial Society of Bone & Joint Surgery.
12. Chua YP, Kwan MK, Ng WM, Saw A. Use of the Tip-apex distance in predicting dynamic hip screw cut out in intertrochanteric fracture of the femur in Asian population. Malaysian Orthopaedic Journal. 2011;5(2):24-7.