

Analysis of the Location, Angle, Radius, and Direction of Curvature in Maxillary Lateral Incisor Roots Using CBCT, in an Iranian Population

Seyed Hossein Razavi¹, Elham Romoozi^{2*}, Mehdi Tabrizzadeh³, Navid Tabavar⁴

¹ Assistant Professor, Department of Oral and Maxillofacial Radiology, Faculty of Dentistry, Shahid Sadoughi University of Medical Sciences, Yazd, Iran. ² Oral and Maxillofacial Radiologist, Kashan University of Medical Science, Kashan, Iran. ³ Department of Endodontics, Dental School, Shahid Sadoughi University of Medical Sciences, Yazd, Iran. ⁴ Graduated Dentist, Shahid Sadoughi University of Medical Sciences, Yazd, Iran

Abstract

Introduction: The risk of error is higher in the treatment of teeth with curved roots, resulting in the reduced success of root canal treatment. Maxillary lateral incisors are more likely to curve in the buccolingual direction. In this study, we aimed to evaluate the curvature of maxillary lateral incisors, using cone-beam computed tomography (CBCT). **Methods:** This descriptive, analytical study was performed on 117 patients, with an average age of 40 years, who were referred to a private radiology center. The curvature angle was measured using the Schneider method, and the curvature radius was determined using the Estrela method. Moreover, the distance between the starting point of the curvature and the cemento-enamel junction (CEJ) was measured using Planmeca Romexis Viewer 2.9.2.R and Geometry Expressions v. 3.0. The collected data were analyzed using SPSS 17. **Findings:** The degree of curvature was classified according to the Seidberg classification. In the coronal view, the curvature degree was mild to moderate; further, severe curvature was quite common (left, 31.2% vs. right, 22.9%). In the sagittal view, the curvature degree was mostly mild, and severe curvature was rarely observed (left, 1% vs. right, 1.8%). The curvature radius was mild in most cases, and most curvatures were distally inclined. The mean distance from the starting point of the curvature to the CEJ was 10.5 mm on the left and 10.2 mm on the right. **Conclusion:** The results indicated a mild to moderate degree of curvature in the root. There was a significant positive correlation between the curvature angle in the coronal view and curvature angle in the sagittal view on both sides.

Keywords: Root curvature, CBCT, Maxillary lateral incisor

INTRODUCTION

One of the most important factors in the success of root canal treatment is complete preparation and cleaning of the root canal system. The remains of microorganisms and infectious pulp in the canal can lead to treatment failure [1]. Failure to detect the root canal curvature can lead to canal cleaning accidents, including loss of working length, deviation from the path of the root canal, strip perforation, root perforation during post-placement, apical root perfusion, breakage of instruments in the canal, and bubbles [2-6]. These avoidable errors reduce the rate of treatment success, especially in necrotic mandibular teeth [7]. In general, the success rate is also lower in teeth with more root curvature [8].

Typically, the root curvature angle and radius are used as the main criteria for measuring the degree of curvature. Since canals with the same curvature angle may have different radiuses, both curvature angle and radius should be determined. In a study by Farida Abesi et al., the mean curvature angle of lateral incisor roots was 12.1 ± 11.2

degrees, and the mean curvature radius was 12.0 ± 5.0 mm in the coronal view [9].

Additionally, in a study by Brita Willershausen et al., the distance from the cemento-enamel junction (CEJ) to the starting point of the curvature was 11.3 ± 2.4 mm on the right

Address for correspondence: Elham Romoozi, Oral and Maxillofacial Radiologist, Kashan University of Medical Science, Kashan, Iran.
E-mail: drromoozi@gmail.com

This is an open-access article distributed under the terms of the Creative Commons Attribution-NonCommercial-ShareAlike 3.0 License, which allows others to remix, tweak, and build upon the work noncommercially, as long as the author is credited and the new creations are licensed under the identical terms.

How to cite this article: Razavi, S. H., Romoozi, E., Tabrizzadeh, M., Tabavar, N. Analysis of the Location, Angle, Radius, and Direction of Curvature in Maxillary Lateral Incisor Roots Using CBCT, in an Iranian Population. Arch Pharma Pract 2018;9(4):4-10.

and 10.8 ± 3.5 on the left maxillary lateral incisors [10]. Furthermore, Schäfer *et al.* reported one curvature in 71% of maxillary lateral incisors and more than one curvature in 6%. In this study, the mean curvature angle was 0 in the lateral view [11].

Three-dimensional cone-beam computed tomography (CBCT), compared with other methods of root curvature assessment, presents images with a higher resolution and provides excellent details in the axial, sagittal, and coronal planes, without superimposition. This method also facilitates morphological examination of the canal by changing vertical and horizontal angles [12]. Therefore, in this study, the curvature of maxillary lateral incisors was evaluated in two coronal and sagittal views, using CBCT radiography in Yazd, Iran.

MATERIALS AND METHODS

In this analytical cross-sectional study, CBCT radiography was performed for patients admitted to a private maxillofacial radiology center. Based on previous studies [9], with a targeted coefficient interval of 95% ($\alpha = 0.5$) and an accuracy of 2% ($d = 2$), the required sample size was estimated to be 117. The inclusion criteria were complete root formation and single canal teeth. The exclusion criteria were previous root canal treatment, crown and post in the canal, periapical lesion, developmental defect of the tooth, and inability to observe CEJ due to insufficient image resolution.

Primary radiographs were acquired using a Planmeca device (Finland) under the following conditions: 84 kV, 12 mA current, exposure time of approximately 13 seconds, 160 μm voxel size, and FOV of 100 \times 80 mm. The images were stored

in the DICOM format on a compact disc. They were then analyzed using Planmeca Romexis Viewer 2.9.2.R in the sagittal and coronal views with the desired brightness and contrast in a dark room (displayed on a 14-inch screen with 1366 \times 768 HD resolutions).

The collected data were recorded in the prepared forms. In order to measure the curvature angle using the Schneider method [13], one line was drawn parallel to the longitudinal axis of the canal, while the second line was drawn from the apical foramen to intersect with the first line at the point where the canal begins to level the long axis of the tooth. The curvature degree was classified according to the Seidberg classification [14], in which angles < 5 degrees indicate mild curvature, 5-25 degrees indicate moderate curvature, and 25-70 degrees represent severe curvature.

In addition, to measure the curvature radius using the Estrela method [15], the distance from the starting point of the curvature (point A) to the apex was measured; for values < 6 mm, half the distance was taken into consideration, while for values > 6 mm, the side length was 3 mm. Then, a quadrilateral was drawn on 2 sides, and the created angle was measured using Geometry Expressions v3.0. The angles of the other sides were fixed at 90 degrees to change the quadrilateral shape as necessary for measuring the curvature angle using the Estrela method. For this purpose, the radius curvature was determined by measuring the distance from the starting point of the curvature to the intersection of 2 lines perpendicular to the midpoints (z_0 in the image). A small radius ($r \leq 4$ mm) indicates severe curvature, a medium radius ($4 < r \leq 8$ mm) indicates moderate curvature, and a large radius ($r > 8$ mm) represents mild curvature.

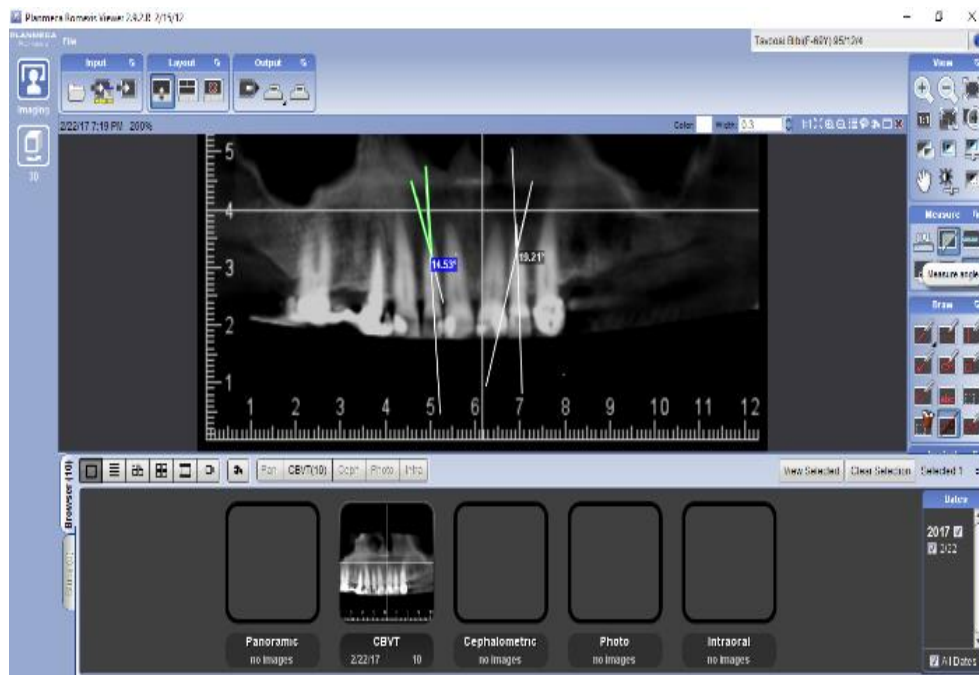


Figure 1. Measurement of curvature angle via the Schneider method

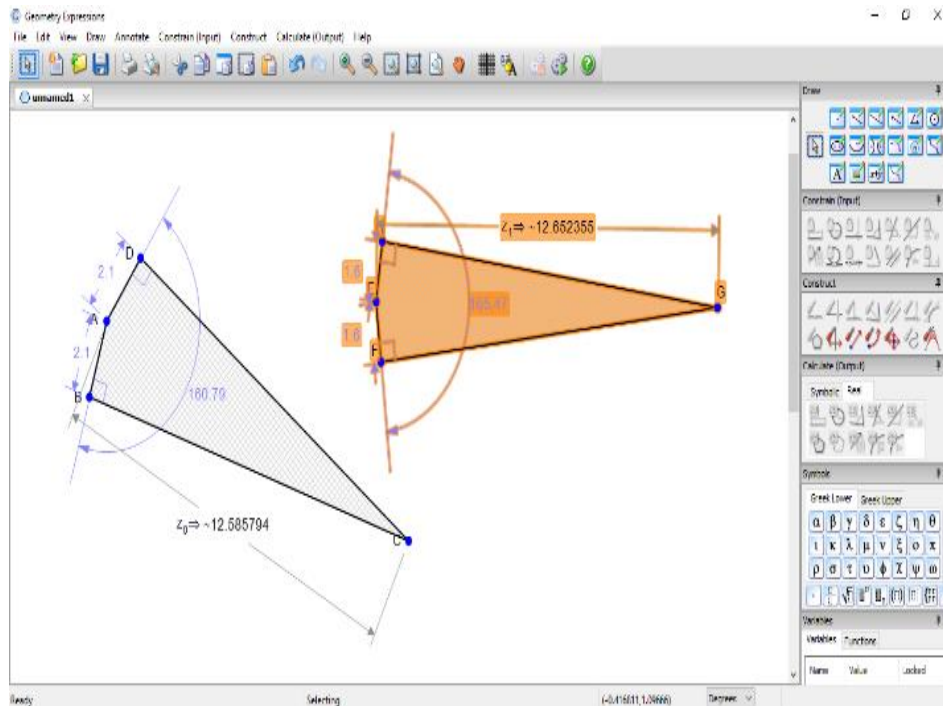


Figure 2. Measurement of curvature radius via the Estrela method

In order to calculate the distance between the starting point of curvature and CEJ, a line was drawn along the mesial to distal aspects at the intersection of the cement and enamel of the tooth, and the distance from the point of curvature to this line

was measured. In the coronal view, the curvature inclination was recorded as mesial, distal, and without curvature, while in the sagittal view, the inclination was recorded as buccal, lingual, and without curvature.

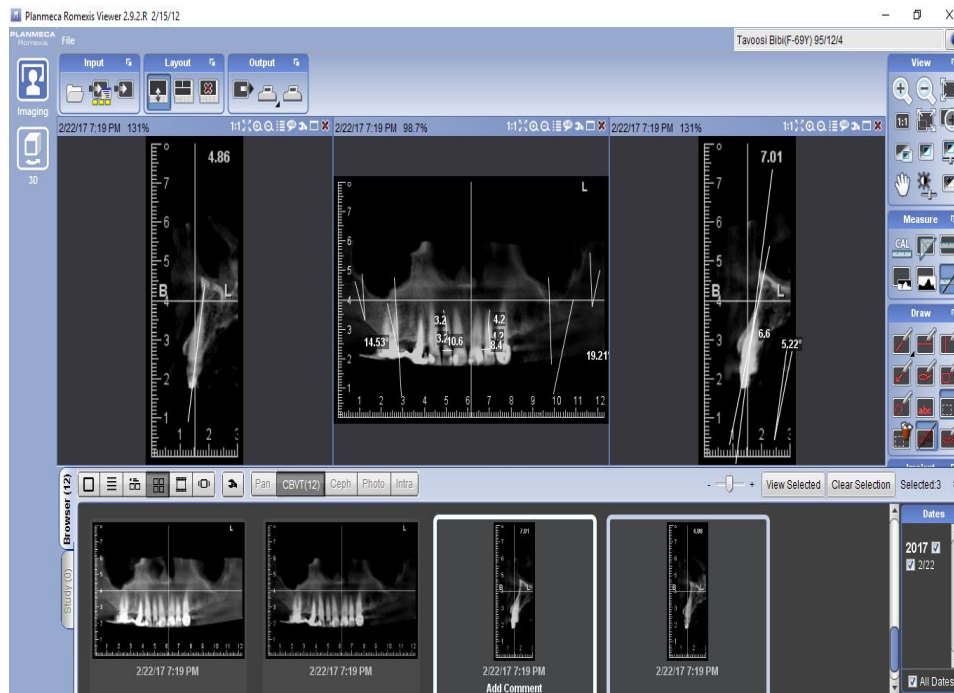


Figure 3. A general representation of the angles and points of curvature in the maxillary lateral incisors

After collecting the data, they were entered into SPSS v. 17, and the tables and figures were plotted. T-tests, analysis of variance, chi-square tests, Fisher's exact tests, and Pearson's

correlation coefficient tests were used for the statistical analysis.

RESULTS

In this study, CBCT radiographic images of maxillary lateral incisors were studied in 117 patients who were referred to a private maxillofacial radiology center. Considering the exclusion criteria, curvature-related variables were measured in 106 left lateral incisors and 109 right lateral incisors. The average age of the participants was 40.6 ± 12.4 years (range, 18 to 73 years). In total, 52 (44.4%) participants were male, and 65 (55.6%) were female.

In the coronal view, the curvature angle was mild to moderate; although severe curvature was also quite common (left, 31.2% vs. right, 22.9%). In the sagittal view, the curvature was mostly mild, and severe curvature was rarely

observed (left, 1% vs. right, 1.8%). The curvature radius was also mild in most observations, and most curvatures were distally inclined. The mean distance from the point of curvature to the CEJ was 10.5 mm on the left lateral incisor and 10.2 mm on the right lateral incisor.

The correlation coefficient was significant for the curvature angle in the coronal view and the curvature angle in the sagittal view on both sides. Therefore, in maxillary lateral incisors, by increasing the curvature angle in the coronal view, the curvature angle in the sagittal view also increases. In contrast to the curvature angle, the correlation coefficient of the curvature radius in coronal and sagittal views was not significant on either side.

Table 1. Correlation coefficients of curvature variables in maxillary lateral incisors

Variables	Correlation coefficient	P-value
Curvature angle in the coronal view with curvature angle in the left sagittal view	0.322	0.001
Curvature angle in the coronal view with curvature angle of the right sagittal view	0.256	0.007
The curvature radius of the coronal view with curvature angle of the left sagittal view	0.041	0.831
The curvature radius of the coronal view with curvature angle of the right sagittal view	0.390	0.110

Table 2. Frequency distribution of curvature direction in maxillary lateral incisors

Side	Curvature direction in the sagittal view	Buccal		Lingual		Without curvature		Total	
		Number	Percent	Number	Percent	Number	Percent	Number	Percent
Left	Mesial	1	0.9	1	0.9	6	5.7	8	7.5
	Distal	4	3.8	23	21.8	40	37.7	67	63.3
	Without curvature	0	0	1	0.9	30	28.3	31	29.2
	Total	5	4.7	25	23.6	76	71.7	106	100
Right	Mesial	0	0	4	3.7	6	5.5	10	9.2
	Distal	5	4.6	8	7.3	37	33.9	50	45.8
	Without curvature	2	1.8	2	1.8	45	41.4	49	45
	Total	7	4.6	14	12.8	88	80.8	109	100

Table 3. Mean starting point of curvature in maxillary lateral incisors

The starting point of curvature	Gender	Number of samples	Mean	SD	Minimum	Maximum	P-value
Left	Male	28	10.6	1.7	6.2	13	0.605
	Female	45	10.43	1.2	7.9	13	
	Total	73	10.49	1.4	6.2	13	
Right	Male	23	10.47	1.7	7.9	14	0.349
	Female	39	10.09	1.4	7.5	13.5	
	Total	62	10.23	1.5	7.5	14	

DISCUSSION

Radiography before a root canal procedure is required to determine the curvature angle, radius, location, and a number of canals in order to reduce errors during treatment and increase the overall success of treatment [16]. Various methods have been proposed for determining the curvature angle and radius [17]. This study aimed to measure the curvature angle using the Schneider method and the curvature radius using the Estrela method, on CBCT images.

According to the results of this study, the highest frequency of curvature direction in maxillary lateral incisors was distal in the coronal view (63.3% on the left vs. 45.8% on the right). In the sagittal view, lack of curvature occurred most frequently (71.7% on the left vs. 80.8% on the right). Similarly, in a study by Farida Abesi *et al.* [18], curvatures were distally inclined in 64.7% of teeth and mesially inclined in 35.3% of maxillary anterior teeth with curvatures in the coronal view; this similarity could be related to the similar race of the participants in these studies.

In this study, the mean curvature radius of maxillary lateral incisors was 8.7 mm on the left and 9.9 mm on the right in the coronal view. Moreover, the mean curvature radius in the sagittal view was 18.1 mm on the left and 13.0 mm on the right. Farida Abesi *et al.* [18] analyzed the curvature of anterior teeth and reported that the mean curvature angle of the lateral teeth was 12.1, and the mean curvature radius was 12.0 mm in the coronal view. This discrepancy could be attributed to differences in radiography and radius measurement in teeth with curvature angle > 20 degrees. However, similar results were reported in a study by L'aya Safi *et al.* [13], which revealed that the mean curvature angle of maxillary lateral incisors was 9.4 degrees, and most curvatures (73%) were distally inclined.

Based on the results of this study, in the coronal view of left maxillary lateral incisors, mild curvature angle had the highest frequency in men (43.5%) and moderate frequency in women (45%). On the right side, mild curvature angle showed the highest frequency in men and women (55.3% vs. 45%). Moreover, in the sagittal view, mild curvature angle had the highest frequency in men and women in the left teeth (78.3% vs. 71.8%). On the right side, a mild curvature angle was reported in 87.2% of men and 79% of women.

In the study by Farida Abesi *et al.* [18], the degree of curvature in the coronal view was mild in 39% of maxillary anterior teeth, moderate in 44%, and severe in 16%. In addition, 2.5% of the canals had a curvature angle < 4 degrees, 19% had a curvature angle of 5-8 degrees, and 78.5% had a curvature angle > 9 degrees. La'ya Safi *et al.* [19] reported that maxillary lateral incisors often have a mild curvature of 5-25 degrees. This finding is in line with our study, which showed that most curvature angles and radiuses in men and women are mild or moderate; this similarity could be attributed to the similar ethnicity of the participants in these studies.

Moreover, Edgar Schäfer *et al.* [11] analyzed the frequency, angle, radius, and length of curvature in the canals of permanent teeth. The measurement of curvature angle in teeth with 1 curvature was performed using the Schneider method [13], while in teeth with more than 1 curvature, the Cunningham and Senia method was applied [2]. The curvature radius was also measured using a different method. It was reported that 84% of all the examined canals had 1 curvature, while 17.5% had 2 curvatures. In this study, 71% of the canals of maxillary lateral incisors had 1 curvature, while 6% had more than 1 curvature. In the clinical view of maxillary lateral incisors, the mean curvature angle was 11 degrees, the maximum curvature angle was 74 degrees, and the mean curvature radius was 5.9 degrees. In the lateral view, the mean curvature angle was 0, the maximum curvature angle was 55 degrees, and the mean curvature radius was 0 mm. The study by Edgar Schäfer *et al.* [11] which is similar to the present study reported most curvatures to be mild and moderate.

Furthermore, in a study by Liu F *et al.* [20], it was reported that the root canal of anterior teeth was mostly typed in the examined population. Most curvatures were moderate and in the apical one-third. The shortest radius and length of curvature were observed in the maxillary lateral incisor, which indicates severe curvature and needs attention during root canal treatment.

Based on the results of this study, the mean distance between CEJ and starting point of curvature was 10.49 mm on the left and 10.23 on the right maxillary lateral incisor. In this regard, in a study by Brita Willershausen *et al.* [10], the mean distance between CEJ and the first curvature of maxillary incisors was 11.3 mm on the right and 10.8 mm on the left in the coronal view. Further, the angle of the first curvature of the maxillary lateral incisor root was 10.9 degrees on the right and 10.7 degrees on the left in the coronal view.

In their study, all the maxillary lateral incisors had curvatures, and the frequency of lateral incisors with 2 curvatures was 20.6% on the right and 20.5% on the left. The differences in the results of this study and the present research can be justified by differences in ethnicity and radiography, as well as the exclusion of teeth with more than 1 curvature in this study.

To reduce the risks in curved canals, dentists can apply modern tools and methods to reduce the occurrence of such problems as much as possible. Therefore, accurate diagnosis and precise information about the root curvature, angle, and inclination are necessary. Moreover, change of conventional lingual access to incisal access, use of periapical radiography along with or instead of apex locator (to increase the accuracy of working length), application of nickel-titanium files for proper cleaning and shaping, and use of warm vertical techniques, such as the Guttafusion and Thermafil techniques to fill the curved canals, are recommended [21-24].

CONCLUSION

The results of this study showed that most curvatures of maxillary lateral incisors are distally inclined. Variables indicating the curvature degree were often mild to moderate, and the difference was not significant between men and women. A significant positive correlation was found between the increase in the curvature angle in the coronal view and the curvature angle in the sagittal view of lateral incisors on both sides.

REFERENCES

1. Byström A, Happonen RP, Sjögren U, Sundqvist G. Healing of periapical lesions of pulpless teeth after endodontic treatment with controlled asepsis. *Dental traumatology*. 1987 Apr;3(2):58-63.
2. Cunningham CJ, Senia ES. A three-dimensional study of canal curvatures in the mesial roots of mandibular molars. *Journal of endodontics*. 1992 Jun 1;18(6):294-300.
3. Zelada G, Varela P, Martín B, Bahillo JG, Magán F, Ahn S. The effect of rotational speed and the curvature of root canals on the breakage of rotary endodontic instruments. *Journal of Endodontics*. 2002 Jul 1;28(7):540-2.
4. Perez E, Zillich R, Yaman P. Root curvature localizations as indicators of post length in various tooth groups. *Dental Traumatology*. 1986 Apr;2(2):58-61.
5. Powell SE, Wong PD, Simon JH. A comparison of the effect of modified and nonmodified instrument tips on apical canal configuration. Part II. *Journal of endodontics*. 1988 Jan 1;14(5):224-8.
6. Hall MC, Clement DJ, Dove SB, Walker III WA. A comparison of sealer placement techniques in curved canals. *Journal of Endodontics*. 1996 Dec 1;22(12):638-42.
7. Lin LM, Rosenberg PA, Lin J. Do procedural errors cause endodontic treatment failure?. *The Journal of the American Dental Association*. 2005 Feb 1;136(2):187-93.
8. Alomairy KH. Evaluating two techniques on removal of fractured rotary nickel-titanium endodontic instruments from root canals: an in vitro study. *Journal of endodontics*. 2009 Apr 1;35(4):559-62.
9. Abesi F, Ehsani M. Radiographic evaluation of maxillary anterior teeth canal curvatures in an Iranian population. *Iranian endodontic journal*. 2011;6(1):25.
10. Willershausen B, Kasaj A, Tekyatan H, Roehrig B, Briseno B. Radiographic investigation of location and angulation of curvatures in human maxillary incisors. *Journal of endodontics*. 2008 Sep 1;34(9):1052-6.
11. Schäfer E, Diez C, Hoppe W, Tepel J. Roentgenographic investigation of frequency and degree of canal curvatures in human permanent teeth. *Journal of endodontics*. 2002 Mar 1;28(3):211-6.
12. Hargreaves KM, Berman LH. *Cohen's pathways of the pulp expert consult*. Elsevier Health Sciences; 2015 Oct 2.
13. Schneider SW. A comparison of canal preparations in straight and curved root canals. *Oral surgery, Oral medicine, Oral pathology*. 1971 Aug 1;32(2):271-5.
14. Seidberg BH, Altman M, Guttuso J, Suson M. Frequency of two mesiobuccal root canals in maxillary permanent first molars. *The Journal of the American Dental Association*. 1973 Oct 1;87(4):852-6.
15. Estrela C, Bueno MR, Sousa-Neto MD, Pécora JD. Method for determination of root curvature radius using cone-beam computed tomography images. *Brazilian Dental Journal*. 2008;19(2):114-8.
16. Basrani B, editor. *Endodontic radiology*. John Wiley & Sons; 2012 Oct 16.
17. Sonntag D, Stachniss-Carp S, Stachniss V. Determination of root canal curvatures before and after canal preparation (part 1): a literature review. *Australian Endodontic Journal*. 2005 Dec;31(3):89-93.
18. Abesi F, Ehsani M. Radiographic evaluation of maxillary anterior teeth canal curvatures in an Iranian population. *Iranian endodontic journal*. 2011;6(1):25.
19. Safi L, Mardani F, Rashid T. Radiographic evaluation of maxillary lateral incisor canal curvature in patients were referred to the endodontics department of dental faculty of shiraz university of medical science in 1380-1381. *Shiraz University of Medical Science Journal*. 2004.
20. Liu F, Wang SF, Zhao SL. Survey of root canal curvature of anterior teeth from Chuang population. *Hua xi kou qiang yi xue za zhi= Huaxi kouqiang yixue zazhi= West China journal of stomatology*. 2009 Oct;27(5):505-8.
21. Yahata Y, Masuda Y, Komabayashi T. Comparison of apical centring ability between incisal-shifted access and traditional lingual access for maxillary anterior teeth. *Australian Endodontic Journal*. 2017 Dec;43(3):123-8.
22. Neuhaus KW, Schick A, Lussi A. Apical filling characteristics of carrier-based techniques vs. single cone technique in curved root canals. *Clinical oral investigations*. 2016 Sep 1;20(7):1631-7.
23. Santhosh L, Raiththa P, Aswathanarayana S, Panchajanya S, Reddy JT, Susheela SR. Influence of root canal curvature on the accuracy of an electronic apex locator: An in vitro study. *Journal of conservative dentistry: JCD*. 2014 Nov;17(6):583.
24. Jafarzadeh H, Abbott PV. Dilaceration: review of an endodontic challenge. *Journal of endodontics*. 2007 Sep 1;33(9):1025-30.